

USE OF MINI IMPLANTS FOR REPLACEMENT AND IMMEDIATE LOADING OF 2 SINGLE-TOOTH RESTORATIONS: A CLINICAL CASE REPORT

Azfar A. Siddiqui, DMD, MSc
Mark Sosovicka, DMD
Mark Goetz, CDT

KEY WORDS

Mini implant
Immediate loading
Single-tooth restoration

Numerous long-term studies have shown that treatment with dental implants can provide edentulous patients with a more stable alternative to complete dentures and partially edentulous patients with a more conservative form of tooth replacement than conventional fixed partial dentures. Until recently, commercially available dental implants have been limited to diameters ranging from 3.0 mm to 7.0 mm. Although this range of diameters has been able to address most clinical needs, partially edentulous patients who could not accommodate a 3.0-mm-diameter implant without damaging adjacent dental structures were excluded from implant therapy. This article reports on the surgical treatment and immediate restoration of a patient who received mini implants that were 2.4 mm in diameter.

INTRODUCTION

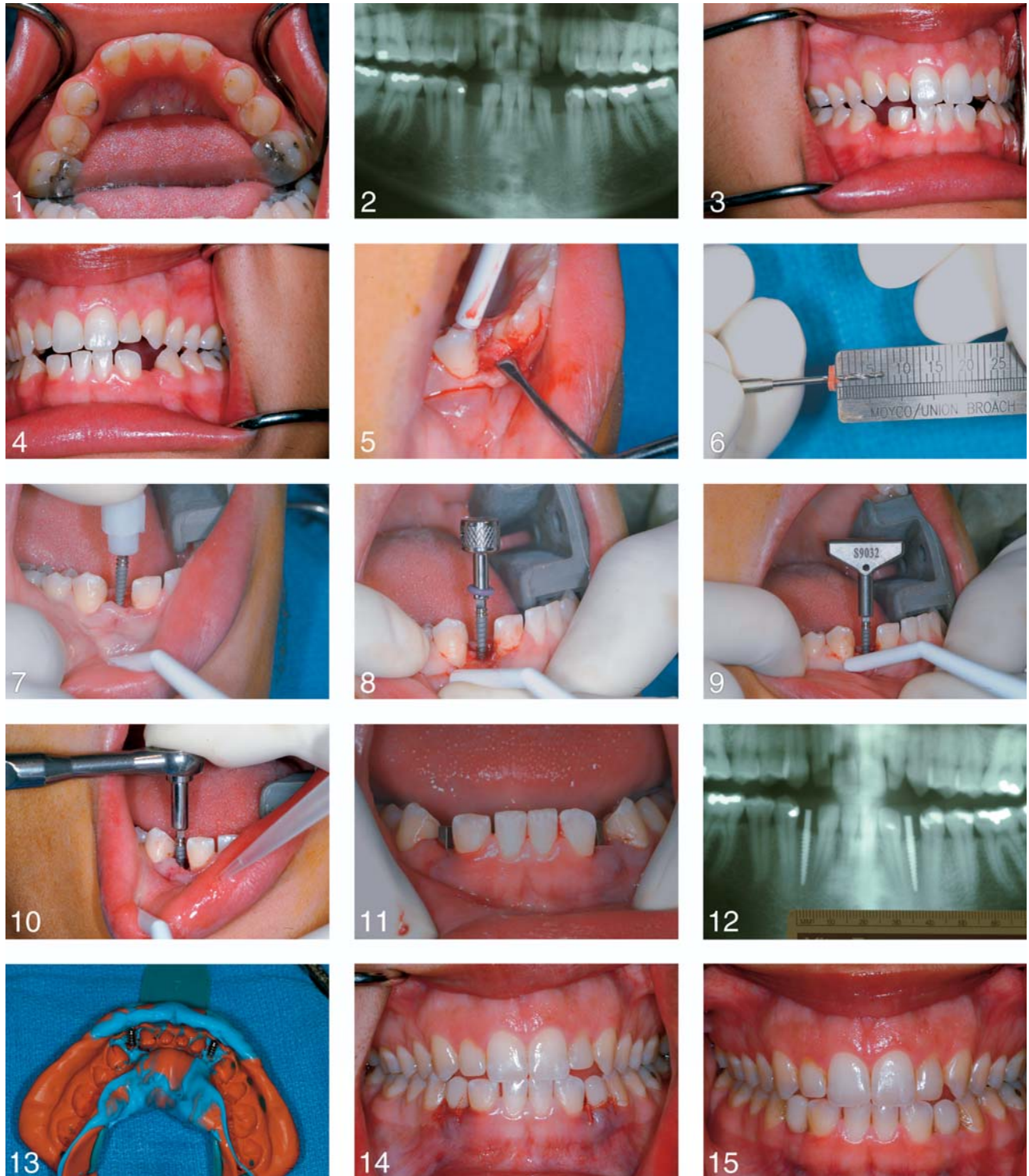
Endosseous dental-implant rehabilitation can provide partially or completely edentulous patients with function and esthetics similar to natural dentition while preserving adjacent teeth.¹⁻³ In clinical situations where residual dentitions are healthy and there are no systemic contraindications, dental-implant therapy may represent the highest standard of care for tooth replacement.

Commercially available dental implants generally range in diameter from 3 mm (ie, "narrow diameter") to 7 mm (ie, "wide body," "wide diameter"), with the vast majority of implants falling

in the "standard diameter" range of 3.7 mm to 4.0 mm.⁴ When placing dental implants in partially edentulous patients, it has been recommended to maintain 2 mm to 3 mm of available space between the surface of the implant and the residual dentition to avoid impinging or damaging the periodontal ligaments of the adjacent teeth.⁵ Unfortunately, some patients have been traditionally excluded from the benefits of implant therapy because they lacked adequate mesiodistal edentulous space to accommodate even a narrow-diameter implant.

Implants with diameters ≤ 2.7 mm (ie, "mini implants") were initially developed for placement in conjunction with standard-

Azfar A. Siddiqui, DMD, MSc, is the director of Maxillofacial Prosthetics, Mark Sosovicka, DMD, is an assistant professor of Oral and Maxillofacial Surgery, and Mark Goetz, CDT, is a senior dental technician in the Department of Maxillofacial Prosthetics at the School of Dental Medicine at the University of Pittsburgh, 3459 Fifth Avenue, Suite 202 South, Pittsburgh, PA 15213. Correspondence should be addressed to Dr Siddiqui.



FIGURES 1–15. FIGURE 1. Patient with congenitally missing mandibular canine teeth. FIGURE 2. Preoperative panoramic radiograph. Note the distal inclination of the lateral incisors. FIGURE 3. Right lateral contacts. FIGURE 4. Left lateral contacts. FIGURE 5. A crestal incision exposed the osteotomy site. FIGURE 6. The 1.0-mm drill with a rubber stopper at a predetermined length. FIGURE 7. A 2.4-mm-diameter mini implant initiated to engage the osteotomy. FIGURE 8. The implant was tightened using the titanium finger driver. FIGURE 9. A winged driver was used when increased resistance was felt. FIGURE 10. A ratchet was only used as a final step to submerge the implant threads. FIGURE 11. Both implants in position. FIGURE 12. Postoperative panoramic radiographs demonstrated the desirable positioning of both implants. FIGURE 13. A final impression was made at the time of surgery. FIGURE 14. Provisional crowns were placed on the day of surgery. FIGURE 15. Placement of the final, implant-supported crowns at the 2-week follow-up appointment.

diameter implants to stabilize and retain an interim prosthesis during the healing phase.^{4,6-8} Other research has suggested that the pull-out strength of endosseous implants may be based on the length rather than the diameter of the implant,⁹ and histologic analysis has shown that mini implants undergo osseointegration comparable to that of larger-diameter implants.¹⁰ These findings have led some clinicians to advocate the use of mini implants to support and/or retain definitive prostheses.¹¹⁻¹³

This article reports on the clinical use of mini implants in a patient with congenitally missing mandibular canines with limited mesiodistal bone dimension.

CLINICAL REPORT

Evaluation and case planning

A 22-year-old female presented for prosthodontic evaluation and rehabilitation of congenitally missing mandibular canines (Figure 1). The patient had undergone orthodontic rehabilitation within the past year and was currently wearing an interim removable partial denture. Her medical history was unremarkable. Clinical and radiographic evaluations revealed slightly less than 5.0 mm of mesiodistal bone in the mandibular left canine location and 5.0 mm of mesiodistal bone in the mandibular right canine location (Figure 2). Despite the recent orthodontic treatment, the lateral incisor roots appeared distally inclined on the radiograph, which further limited the available space for the safe placement of a standard-diameter implant.

Occlusal analysis revealed an important finding of group function in lateral excursions, with infraerupted opposing dentition providing minimal-load potential

in the area of the missing teeth (Figures 3 and 4). Given the mesiodistal limitations of both edentulous spaces and the possible weakness of the adjacent mesial abutments, a conventional fixed prosthesis would necessitate splinting the prosthesis from the central and lateral incisors to the first premolar bilaterally. Thus, an 8-unit, fixed partial denture would be needed to replace the 2 missing teeth. The patient rejected this radical approach to achieve a fixed restoration. Although a removable partial denture may have provided reasonable function, the patient considered a removable appliance unacceptable and preferred implant replacement of her missing teeth.

Although limited mesiodistal edentulous spaces contraindicated the placement of standard-diameter implants, mini implants would also normally be contraindicated in locations with heavy lateral occlusal contacts. In this particular case, however, most of the lateral load was shared by the posterior teeth, and it was felt that mini implants could be safely used. The treatment plan and alternatives were thoroughly reviewed, and the patient provided signed informed consent prior to surgery.

A single-stage mini implant (Imtec Sendax MDI, Imtec Corporation, Ardmore, Okla) 2.4 mm in diameter with an intraosseous depth of 15 mm was selected to support a single-tooth restoration in each edentulous location.

Surgical procedures

The patient was prescribed 500 mg of amoxicillin 3 times a day for 7 days and instructed to start prophylactic antibiotic therapy 1 day prior to implant surgery. On the day of surgery, the patient

was administered local anesthesia.¹⁴ A small crestal incision was made, and a minimal, full-thickness, mucoperiosteal flap was reflected to ensure that the implant threads were properly submerged in the bone, as well as to centrally position the implant in the available edentulous space (Figure 5).

The technique for placement of the mini implant consisted of a single drill that was 1.0 mm in diameter and used a rubber stopper placed at a predetermined length (Figure 6). The pilot hole was only drilled to half or less of the implant length to be used, depending on the bone quality, and the implant was auto-advanced until full placement was achieved.¹⁰⁻¹³ In type II bone,¹² it was recommended that the rubber stopper should be placed at no more than half the intended depth of the implant.¹² Following this recommendation, the stopper was carefully placed on the drill at 7.5 mm because the intraosseous portion of the implant to be used was 15 mm in length (Figure 6).

Surgical entry with the 1.0-mm-diameter bur was performed in the presence of copious irrigation. Because only 1 bur would be used prior to placing the implant, a slow-penetration technique was used to ensure that the angle was correct relative to the adjacent dentition and planned prosthesis.¹⁵ The 5.0-mm mark was reached very quickly because the bone quality was closer to the more-porous type III¹⁶ bone than the anticipated type II¹⁶ bone. For this reason, further penetration with the drill was abandoned and a 2.4-mm-diameter implant was selected in accordance with the implant manufacturer's recommendation for type III bone quality. Primary implant stability or lack of micromotion is critical in

implant survival and success,^{17,18} and placement of a slightly wider implant was aimed at achieving this objective. A periapical radiograph was taken with the pilot drill in place to confirm proper angulation of the osteotomy at the depth of 5.0 mm.¹⁹

A 2.4-mm implant was initiated (Figure 7) into the site and placed first with a titanium finger driver (Figure 8) and then with a winged driver (Figure 9) according to the manufacturer's protocol. The ratchet was used only for the final few turns when resistance increased (Figure 10), and extreme care was used not to fracture the implant.¹² In the authors' experiences, if considerable tactile resistance is encountered the implant should be reversed a few turns, irrigated with sterile saline, and slowly retightened. In most situations, this will place the implant to the desired depth. Only in rare conditions where the inferior cortical plate is being engaged will the clinician need to remove the implant in its entirety, use the pilot bur again to deepen the osteotomy, and then place the implant. After placement, primary implant stability was evaluated with a torque wrench calibrated to 35 Ncm according to the manufacturer's recommendation. The same surgical procedures were repeated contralaterally for the missing left mandibular cuspid (Figure 11).

Primary soft tissue closure was achieved using a conventional mattress-suturing technique with Vicryl 4.0 sutures (Ethicon, Sommerville, NJ). A postoperative Panorex radiograph (Figure 12) revealed desirable mini-implant placement in the mesiodistal centers of the edentulous spaces without compromising adjacent teeth. A definitive impression (Reprosil, Dentsply Caulk, Milford, Del) using impression

copings (Imtec Sendax MDI) was made at the time of surgery (Figure 13). Interim bis-acrylic composite crowns (Luxatemp, DMG Hamburg, Germany) were fabricated with an indirect technique and cemented on the same day using provisional cement (Improv, Nobel Biocare, Yorba Linda, Calif). The interim crown was kept out of occlusion, with minimal interproximal contacts. This approach is defined as *nonfunctional immediate loading*.²⁰ These interim crowns were meant merely for esthetics rather than function (Figure 14). The patient was provided with home care instructions and discharged.

Ten days after surgery, the patient was recalled for evaluation and reported only minimal discomfort postoperatively. The tissues were healing in an acceptable manner, and the implant-supported crowns exhibited no visible mobility to manual testing. The definitive implant-supported crowns were delivered within 2 weeks of surgery, which is considered to be immediate or immediate-delayed occlusal loading (Figure 15).²⁰ The maxillary lateral incisors were subsequently restored with incisal composite restorations to improve esthetics, but were still left out of occlusal contact.

DISCUSSION

Dental implants are now considered the treatment of choice for replacement of all forms of tooth loss. Apart from providing function and esthetics similar to natural dentition, they also provide the most conservative treatment option, especially for single-tooth restoration. Until recently, dental-implant treatment was limited to patients with a minimum of 7 mm to 8 mm of available mesiodistal

bone width to enable the placement of a 3.0-mm-diameter implant without impinging on the roots of the adjacent teeth. The availability of mini implants 1.8 mm and 2.2 mm in diameter, and FDA approval for use as definitive prosthesis support and retention, has opened new dimensions in oral-implant restoration. Mini implants obviously have less surface area available for osseointegration compared to narrow-diameter implants, and this may be a handicap in some clinical situations. In the present case report, the patient's minimal mesiodistal space precluded the use of narrow-diameter implants, but also presented a very favorable occlusal scheme that enabled immediate loading of two 2.4-mm-diameter implants with single-tooth restorations. Apart from a conservative approach and no adjacent tooth modification, additional benefits to the patient were reduced cost and fixed restorations.

CONCLUSIONS

Mini implants are indicated for areas where the use of narrow-diameter implants (≥ 3.0 mm) are contraindicated. Until long-term longitudinal clinical data on mini dental implants are unavailable, their use should be limited to areas with potentially less occlusal load.

REFERENCES

1. Adell R, Lekholm U, Rockler B, Branemark P-I. A 15 year study of osseointegrated implants in the treatment of the edentulous jaw. *Int J Oral Surg.* 1981;10:387-416.
2. Branemark P-I. Osseointegration and its experimental background. *J Prosthet Dent.* 1983;50:399-410.
3. Taylor TD, Agar JR. Twenty years of progress in implant prosthodontics. *J Prosthet Dent.* 2002;88:89-95.

4. Lee J-H, Frias V, Lee K-W, Wright RF. Effect of implant size and shape on implant success: a literature review. *J Prosthet Dent.* 2005;94:377-381.
5. Hobo S, Icida E, Garcia LT. *Osseointegration and occlusal rehabilitation.* Chicago, Ill: Quintessence Publ Co Inc; 1989.
6. Nagato M, Nagaoka S, Mukunoki O. The efficacy of modular transitional implants placed simultaneously with implant fixtures. *Compend Contin Educ Dent.* 1999;20:39-46.
7. Simon H, Caputo AA. Removal torque of immediately loaded transitional endosseous implants in human subjects. *Int J Oral Maxillofac Implants.* 2002;17:839-845.
8. el Attar MS, el Shazly D, Osman S, el Domiati S, Salloum MG. Study of the effect of using mini-transitional implants as temporary abutments in implant overdenture cases. *Implant Dent.* 1999;8:152-158.
9. Block MS, Delgado A, Fontenot MG. The effect of diameter and length of hydroxyapatite-coated dental implants on ultimate pullout force in dog alveolar bone. *J Oral Maxillofac Surg.* 1990;48:174-178.
10. Balkin BE, Steflink DE, Naval F. Mini dental implants insertion with auto advance technique for ongoing applications. *J Oral Implantol.* 2001;27:32-37.
11. Rossein KD. Retaining and stabilizing dentures with narrow-bodied implants. *Dent Today.* 2005;24:100, 102-106.
12. English CE, Bohle GC III. Diagnostic, procedural, and clinical issues with Sendax Mini Dental Implants. *Compend Contin Educ Dent.* 2003;24(suppl 1):3-25.
13. Gibney JW. Minimally invasive implant surgery. *J Oral Implantol.* 2001;27:73-76.
14. Heller AA, Shankland WE II. Alternative to inferior alveolar nerve block anesthesia when placing mandibular dental implants posterior to the mental foramen. *J Oral Implantol.* 2001;27:127-133.
15. Kawahara H, Kawahara D, Hayakawa M, Tamai Y, Kuremoto T, Matsuda S. Osseointegration under immediate loading: biomechanical stress-strain and bone formation resorption. *Implant Dent.* 2003;12:61-68.
16. Lekholm U, Zarb G. Patient selection and preparation. In: Branemark P-I, Zarb G, Albrektsson T, eds. *Tissue Integrated Prosthesis.* Chicago, Ill: Quintessence Publ Co Inc; 1985: 199-209.
17. Szmukler-Moncler S, Salama H, Reingewritz Y, et al. Timing of loading and effect of micromotion on bone-dental implant interface: review of experimental literature. *J Biomed Mater Res.* 1998;43:192-203.
18. Brunski JB, Pules DA, Nanci A. Biomaterials and biomechanics of oral and maxillofacial implants: current status and future developments. *Int J Oral Maxillofac Implants.* 2000;15:15-46.
19. Lewis S, Avera S, Engleman M, Beumer J III. The restoration of improperly inclined osseointegrated implants. *Int J Oral Maxillofac Implants.* 1989;4:147-152.
20. Misch CE, Wang H-L, Misch CM, Sharawy M, Lemons J, Judy KW. Rationale for the application of immediate load in implant dentistry: Part I. *Implant Dent.* 2004;13:207-217.