

Fixed Partial Dentures and Crowns Supported by Very Small Diameter Dental Implants in Compromised Sites

Dennis Flanagan, DDS

After trauma or years of bone resorption patients can present for implant treatment with variable amounts of bone volume, length and height of ridge, and interocclusal space. Some sites cannot accept the standard sizes of many available implants without site development. Bone augmentation is an option for increasing the available bone volume if a standard diameter implant is required by the clinician. Standard diameter implants are in the range of 3.75 to 4.2 mm. However, in the non-esthetic zone an increase in bone volume by augmentation procedures may not be required. There is some debate as to the true supportive quality of grafted bone.¹ Extra-cortical grafted bone has been known to resorb after placement.¹ Bone formed in grafted areas can become trabecular but there is no evidence that grafted bone progresses to cortical bone. Implant support depends on cortical bone. If grafted bone does not resist occlusal forces then the presenting natural base of bone is the sole means of support for the restoration.¹

Some residual ridges are very thin and will not accept a standard diameter (3.75–4.1 mm) implant within the confines of the available bone with a 1 to 2 mm of bone circumferential thickness. Small coronal dehiscences may be grafted or ignored by placing the implant slightly deeper to account for any anticipated osseous crest resorp-

Very small diameter (1.8–3.3 mm) dental implants may be successfully used to support fixed partial dentures in edentulous sites of compromised bone width or length. Very small implants can be successfully used in highly selected sites where there is adequate bone density and bone volume for immediate implant stability. Adequate or augmentable attached gingiva may be a requirement. A small diameter implant presents less of an obstacle for angiogenesis and there is less percutaneous exposure and bone displacement

as compared with standard sized implants. In posterior sites, rounded and narrow prosthetic teeth present small occlusal tables to minimize axial and off-axial directed forces. Multiple splinted implants may be necessary to minimize metal fatigue from cyclic loading. Anterior restorations supported by mini implants may need occlusal relief to minimize the effects of cyclic loading. (Implant Dent 2008;17:182–191)

Key Words: mini implant, occlusal scheme, bone density, bone ridge

tion. A smaller diameter implant may be considered. There are small diameter implants available in a range from 3.0 to 3.3 mm. Also available are very small or “mini” 1.8 to 2.5 mm diameter implants. These implants have been used primarily in multiples to retain complete removable overdentures in the maxilla and mandible.^{2,3} The term mini has also been used to describe very short length implants with standard or larger diameters.⁴ There are case reports that demonstrate where compromised sites are restored with 1.8 to 3.3 mm diameter implants that support fixed partial denture prostheses.^{5–7} These implants have been used primarily as transitional or as temporary implants to support temporary prostheses although larger implants are undergoing osseointegration.

However, these very small diameter implants, when used individually or in multiples or in combination with larger sized implants, may offer adequate sup-

port for crowns or fixed partial dentures in selected circumstances.

CASE GP

The patient, a 42-year-old man, presented for restoration of his missing teeth #24 and 25 (Figs. 1–3) (Table 1).⁵ Retained deciduous central incisors were without succedaneous incisors. Radiographs and study casts were made for analysis. His occlusion was a Class II division 2 with a 100% overbite compromising the interocclusal available space. Occlusal abrasion had occurred, further reducing the available interocclusal space. After the deciduous teeth were removed the ridge contour was mapped using a bone sounding technique. The site had adequate height but the width was too narrow and length of the ridge was 11 mm. Clearly, standard width implants would not fit in the space available without orthodontic treatment but after a consultation the patient declined treatment. The ridge length

Private practice, Willimantic, CT.

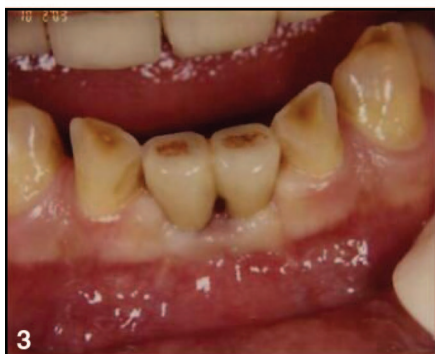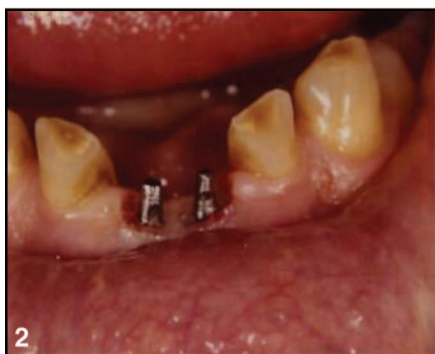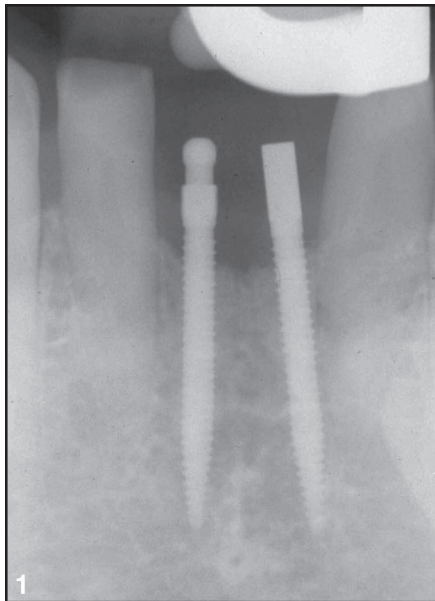


Fig. 1. Two mini implants were placed to replace absent succedaneous mandibular incisors.

Fig. 2. The coronal portions of the implants were slightly prepared for parallelism.

Fig. 3. A 2 unit splinted fixed partial denture was constructed and cemented with zinc phosphate cement. There has now been 4 years of uneventful function.

would not allow proper placement of small diameter 3.25 mm implants. There ideally needs to be 3 mm between each implant and 1.5 mm between each implant and its adjacent tooth, totaling 12.5 mm including the diameter of the im-

plants, exceeding the 11 mm available length. Options for treatment were discussed. The placement of small 1.8 mm implants and subsequent construction of a fixed prosthesis replacing teeth #24 and 25 was then decided upon. The patient accepted the treatment plan and that no provisional restoration would be placed during the healing integration or prosthetic construction phases.

The area was infiltrated in the anterior mandible, facially and lingually, with 1.8 mL of articaine. A vacuum-formed surgical guide was used. A split thickness apically positioned flap was raised with a #15C scalpel to increase the resulting zone of attached gingiva. Each osteotomy was started with a #4 round burr. Then a 1.2 mm drill was used to complete the osteotomy to a 15 mm depth. Type II bone was encountered. Only external irrigation was used. The implants were placed with a specific technique as described by the manufacturer. The implant was placed and turned with a thumb wrench device. A ratchet device is used to complete the placement. When turning becomes difficult, after one complete turn of the implant, a waiting time of 1 minute is observed to allow the bone to recover from the compression of the advancing implant. The implants were placed without incident (Fig. 1). Inventory forced the use of 2 different coronal designs. The patient was instructed in after-care and prescribed chlorhexidine oral rinse. He returned at 1 week for follow-up and had healed well with no complications. An integration/healing phase of 11 weeks was observed, whereupon he returned for construction of a fixed prosthesis. The anterior mandible was again infiltrated with a small amount of articaine (0.4 mL) (Septocaine) for gingival anesthesia. The coronal portion of each implant was slightly prepared with a fine diamond burr to achieve parallelism and to accept splinted crowns (Fig. 2). Impressions were made with a polyvinyl siloxane material. No provisional prosthesis was made. A 2-unit porcelain fused to noble alloy metal splint was constructed that avoided direct centric and excursive contacts. The dental laboratory technician was instructed to apply an extra layer of die separator to insure a passive fit. Two weeks later the es-

thetics and function of the constructed prosthesis were evaluated. The prosthesis was cemented with zinc phosphate cement. The patient has successfully functioned with the prosthesis with no complications for 4 years (Fig. 3).

CASE SR

A 61-year-old woman had a carious tooth #30 extracted (Figs. 4–6) (Table 1). After 4 months of healing, two 2 × 1.5 mm implants (Intra Lock, Ultimatics, Ardmore, OK) were placed and restored with a 2 unit porcelain fused to metal crown splint.

CASE VM

A 42-year-old woman lost #30 due to failed endodontic therapy (Figs. 7–10) (Table 1). The tooth was sectioned and atraumatically extracted and the site allowed to heal for 4 months. Two one-piece 3 mm × 12 mm (BioHorizons) were placed flaplessly by infiltration local anesthesia (articaine). After 4 months waiting for osseointegration, the coronal ends were prepared for splinted crowns. The crowns were cemented with zinc phosphate cement. The patient has been functioning successfully for 2 years.

CASE JC

A 40-year-old man had lost his mandibular right posterior teeth (Figs. 11–13) (Table 1). The site at #28 was adequate but the edentulous site at #29–32 was very narrow, precluding implant placement without extra-cortical bone grafting. Four 2 × 1.5 mm (IntraLock) and a 4 × 0 mm (3-I) implants were placed and restored with a splinted fixed partial denture.

DISCUSSION

Small diameter implants have been used for retention of complete removable maxillary and mandibular overdentures but there are also reports for their use in fixed prosthetics (Fig. 14).⁵

Table 1 lists 25 patients who were treated with very small implants that support fixed partial dentures and have been in service for at least 2 years. The patients received a multiple of very small diameter or combination of small, very small, and standard-sized diameter

Table 1. Table of Patients Treated With Very Small Diameter Implants That Support Fixed Partial Dentures and Crowns

Patient	No. Implants	Implant Sites	Implant Sizes	Deemed Bone Type	Comments
PW	3	18, 19	2 × 10	II	Flapless
PW-2	3	30, 31	2 × 10	II	Flapless
GP	2	24–25	1.8 × 15	II	Apically positioned flap
TS	3	17, 18, 19	Two-2 × 10, 2 × 11.5	III	Flapless
JC	5	28–32	3 × 13, 2 × 10	II	#28 Immed. site
MS	3	24, 25, 26	Two-3.25 × 13, 1.8 × 18	II	#24 + 2 Immed. sites
MD	2	19	2 × 13	II	Flapless
SM	3	28, 29, 30	Two-2 × 10, 2 × 13	III	Flapless
BN	3	18, 19, 20	4 × 10, 3.25 × 10, 2 × 10	III	Apically positioned flap
BN-2	2	25, 27	3.25 × 13, 2 × 15	II	Apically positioned flap
FS	2	19	2 × 10	II	Flapless
RK	3	30, 31, 32	2 × 10	III	Apically positioned flap
CM	2	24, 25	2 × 15	III	Flapless
BL	2	19, 20	2 × 10	II	Apically positioned flap
PS	3	28–31	3 × 12, two-2 × 10	II	Apically positioned flap
PS-2	2	18, 19	2 × 10	II	Flapless
RG	2	19	2 × 10	III	Free gingival graft
RG-2	2	30	2 × 10	III	Flapless
BM	2	19	3.25 × 10, 2 × 10	III	Flapless
AS	4	19–25	Two-3.25 × 10, two-2 × 10	I	Apically positioned flap
BD	2	30	2 × 10	II	Apically positioned flap
mL	2	30, 31	4 × 7, 2 × 10	II	Apically positioned flap
LH	2	19, 20	2 × 10, 4 × 10	II	#20 Delayed placement
CR	4	25–29	Three-1.8 × 15, 2 × 15	III	Flapless
RH	3	23–25	1.8 × 18	II	Immed. placement
CS	2	24, 25	2 × 15	II	Apically positioned flap
AP	3	8, 9, 10	3.25 × 13, 2 × 13, 4 × 15	III	Immed. functional load
BR	3	29, 30, 31	2 × 10	II	Apically positioned flap
VM	2	30	3 × 12	II	Flapless

All prostheses have been in uneventful service for at least 2 years.

implants. These cases demonstrate that single and multiple very small implants may successfully support crowns or fixed partial dentures where there is appropriate bone and occlusal considerations. These sites are usually found in the posterior mandible and anterior maxilla and mandible.

Because bone volume and quality and ridge length can present the implantologist with a challenge for restorative treatment, creative but effective solutions may need to be considered. An up-to-date knowledge of the array of implant sizes and shapes is an asset for treatment.

There are implant diameters available from 1.8 to 7 mm, intuitively; a smaller diameter implant may present less of an impediment or obstacle for angiogenesis to the peri-implant bone. However, there also should be adequate bone density to resist occlusal forces placed on the implants via fixed prostheses. The smaller surface area and volume of these implants places

more force per square millimeter against the encasing bone than larger diameter implants, so there needs to be occlusal force control.

Bone density of type I, II or III, bone site length of at least 4 mm, bone available height of at least 10 mm and at least 1 mm of attached or augmentable gingiva are desirable. Any intraoral location that exhibits these qualities may be appropriate. However, less dense bone may require the use of longer small diameter implants to resist occlusal forces and present less per square millimeter of bone compression during service. That is, during function, lateral occlusal forces will exert a greater per square millimeter force against the supporting bone with smaller diameter implants than larger diameter implants. If the bone cannot resist this lateral compressive force the implant may move in the bone and fibrous replacement may be initiated resulting in implant failure.

Conversely, there may be physiologic advantages to very small diameter implants. An advantage that very small diameter implants have over standard diameter implants is the lesser amount of linear or circumferential percutaneous exposure and bone displacement. The circumference of a 2 mm implant is ($\pi \times \text{diameter}$) 6.28 mm whereas the circumference of a standard 4.0 mm diameter implant is 12.56 mm. The very small implant has half of the linear percutaneous exposure thus exposing less of the implant-gingival attachment to bacterial attack.

There is also a smaller silhouette of the very small diameter implant that may present a barrier to angiogenesis and osteogenesis. Because dental implants are cylinders or near-cylinders, a mathematic calculation of the outline form or the silhouette area, of a 2 × 10 mm implant may be compared with a 4 × 10 mm implant. Where the area is diameter (width) × height. So, 2 × 10 mm = 20 mm² and 4 × 10 mm = 40

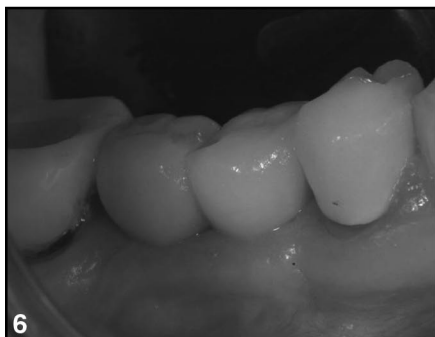
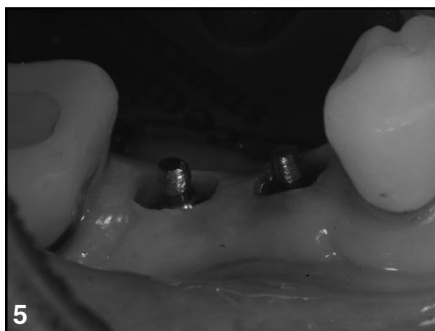
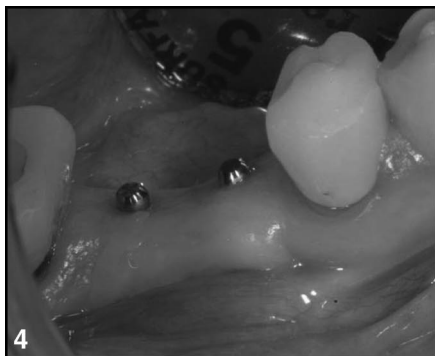Fig. 4. Two implants were placed to support 2 unit splinted crowns to replace #30.

Fig. 5. The coronal portions of the implants were slightly prepared for parallelism.

Fig. 6. A 2 unit porcelain fused to noble alloy splint was constructed. The splint was constructed with a flat rounded occlusal table to minimize off-axial forces and cemented with zinc phosphate cement.

mm². The 2 mm diameter implant presents a barrier to the osseous physiology that is half that of the 4 mm diameter implant.

With respect to volume of the cylinder, where volume = ($\pi = 3.14$) \times (radius squared) \times (cylinder height), then $3.14 \times \text{square mm} \times 10 \text{ mm} = 31.4 \text{ mm}^3$ and, $3.14 \times \text{square mm} \times 10 \text{ mm} = 125.6 \text{ cm}^3$.

So to compare these volumes: $125.6/31.4 = 4$.

The 4 mm diameter implant has 4 times the osseous displacement as compared with the 2 mm diameter

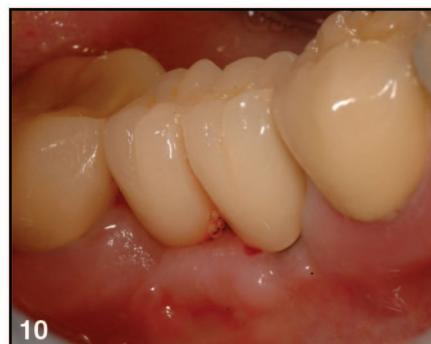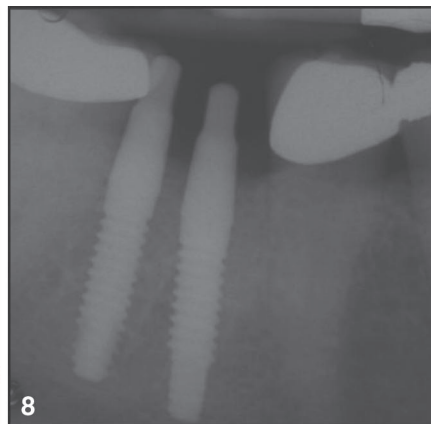

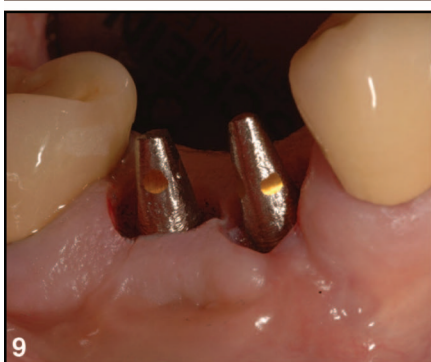
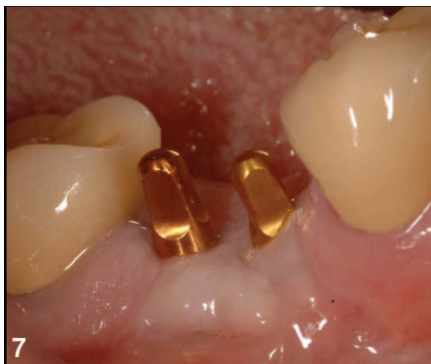Fig. 7. Two 3 mm diameter implants (BioHorizons) were placed to restore #30.

Fig. 8. Radiograph of two 3 mm diameter implants placed to replace #30.

Fig. 9. Coronal portions of the implants were slightly prepared for parallelism.

Fig. 10. A 2 unit porcelain fused to noble alloy splint was constructed. The splint was constructed with a flat rounded occlusal table to minimize off-axial forces and cemented with zinc phosphate cement.

implant. This difference may be important. Intuitively, this may be a physiologic advantage for the very small diameter implant in that there may be more of an available osseous blood supply for the implant supporting bone or less of a barrier. In larger diameter implants this larger barrier to blood supply or angiogenesis may contribute to the classic "resorption to the first thread" in the larger implant. The larger barrier may hinder angiogenesis and subsequent osteogenesis around a newly placed implant. Blood supply at the osseous crest may be hindered by the larger implant and produce the characteristic resorption to the first thread. This phenomenon does not seem to be prevalent with the 2 mm diameter implants. Figure 15 shows 3 implants of different diameter that were placed together in a row in varying widths of bone (Fig. 15). The widest 4.1 mm diameter implant on the left demonstrates bone loss to the first thread. The implant located in the middle is a 2 mm diameter implant and

shows little or no radiographic bone loss. The right implant is a 3 mm diameter implant and shows slight bone loss. The 2 smaller diameter implants are 1 piece, that is, they have no screw retained abutment. There has been some discussion about the gap between the implant fixture and the implant abutment, the so called "microgap" that may be a bacterial reservoir that may cause bone resorption to the first thread. The relative importance of the implant diameter versus abutment microgap has yet to be elucidated.

This crest bone resorption phenomenon does not occur in submerged implants but only after second stage uncover and placement of an abutment. With the very small 2 mm diameter implants this does not seem to be prevalent. This may be the result of the smaller diameter and/or the lack of an abutment with a microgap.

The available bone for an implant site in many cases can leave much to be desired. In these cases, the occlusion, a reduced vertical dimension and

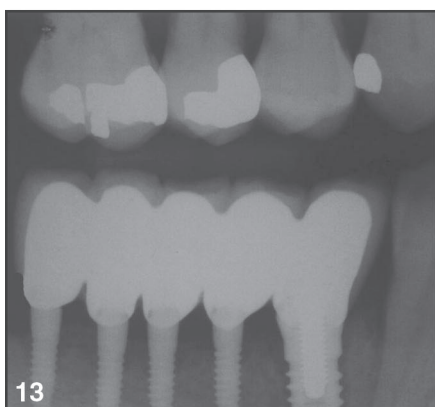
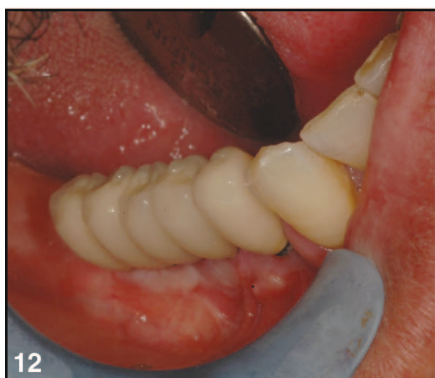
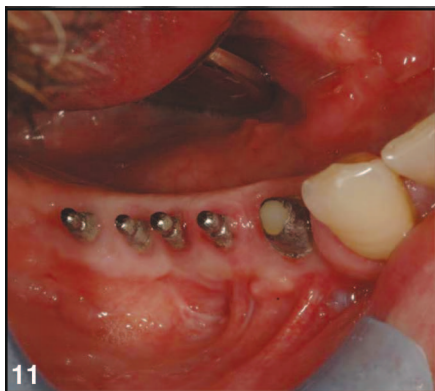Fig. 11. Two different brands (3-I and IntraLock) and diameters (4.1 and 2 mm, respectively) were used to appropriately fit into the edentulous site. Adequate bone volume at site #28 enabled placement of the standard sized implant. The narrow edentulous width at sites #29–32 only accepted very small diameter implants.

Fig. 12. These implants support a splinted 5 unit fixed partial denture opposing natural dentition.

Fig. 13. A radiograph of the multiple small diameter implant with the splinted prosthesis in place.

ridge length can present a dimensional problem for space. Very small diameter implants can fit into many of these atrophic sites with adequate interimplant and interocclusal spacing. Esthetics may be a problem in certain sites and caution is advised here.

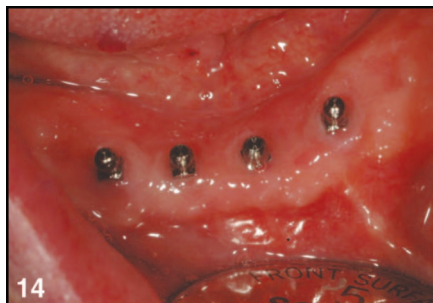


Fig. 14. Multiple very small diameter implants have been used for many years in clinical practice to retain mandibular overdentures. For successful treatment, adequate bone density, bone volume and attached gingiva are appropriate.

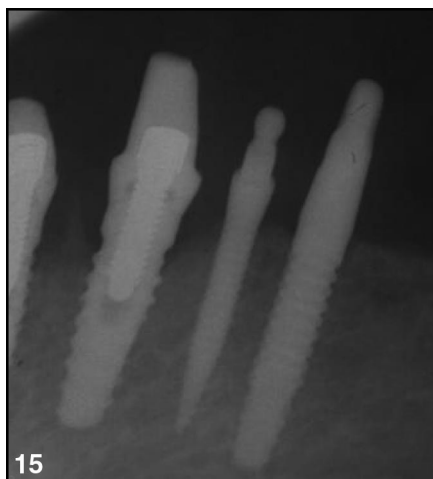


Fig. 15. Radiographic bone loss, typical to 4.1 mm standard diameter implants, is evident on the far left implant, and slight radiographic bone loss is seen on the 3 mm diameter implant at the far right, but no apparent bone loss is evident on the 2 mm diameter implant in the middle.

There needs to be adequate bone density and volume for implant stability and protective attached gingiva to accept an implant supported restoration. These very small diameter implants can fit into sites that cannot accept standard diameter implants without augmentation. The implants in these case series were generally placed flaplessly or with a split thickness apically positioned flaps thus retaining the periosteum and its blood supply and retaining or increasing the attached gingiva. The bone in these atrophic sites is typically type I or II and well suited for initial implant stability.

Very small diameter implants have been used for many years in completely edentulous cases to retain

overdentures without bone grafting. Extracortical bone augmentation grafting may delay implant placement and the resulting grafted bone may not be truly supportive for the implant for many months or years or possibly never.

The bone at the crest of a thin atrophic ridge may be dense cortical bone, which can be very supportive for implants. Posterior sites in the mandible, not in the esthetic zone, may be appropriate for very small diameter implants that support a fixed partial denture. The forces in the posterior jaws can be greater than 1000 N of force but this magnitude is in the axial direction of the implant.⁸ The off-axial vector directive of these forces is much less.

The cyclic loading that characterizes human occlusion may induce metal fatigue in very small diameter implants. Very small diameter implants may need to be used in multiples to preclude cyclic loading metal fatigue and implant fracture in the posterior mandible⁹ (Figs. 7, 11). Unpublished proprietary company (Intralock) data and unpublished data from the author suggests that single 2 mm diameter implants can withstand cyclic direct horizontal coronal loads of 200 N of more than a million cycles. This force represents the maximum force in the anterior jaws that may be humanly generated in the vertical or occluso-apical direction but this force was applied directly horizontally or facio-lingually for the test.

In anterior sites that have adequate width but inadequate length, a very small implant may be appropriate for a single implant.^{5,10} The forces in the anterior jaws can be about a third of the posterior forces, 50 to 200 N. These forces in occlusion, however, are delivered not axially but off axially, a vulnerable direction for the implant. This may require more dense bone to resist the higher per square millimeter force placed on the bone by the smaller diameter implant body. Denser bone may preclude micromovement of the implant and failure of the implant by fibrous replacement. The crowns in these cases may be best left slightly or somewhat out of occlusal contact in centric position and all excursions.

Case selection is critical for the use of very small diameter implants

supporting fixed partial dentures. A patient may be a candidate for these implants if there are milder jaw forces, sites with denser bone with adequate attached gingiva.

The laboratory should be made aware of the very small abutment and the specifics of the occlusal scheme. Laboratory die material may be made of polyurethane (PolyDie, Guilford, CT). This polymeric die material is injected into the impression and the thin coronae of the implants can be reproduced for the working cast. The resulting hard cast is then prepared for conventional crown and bridge techniques. A metal cervical collar and a half lingual coverage may be needed to support the porcelain of a porcelain fused-to-metal crown or fixed partial denture.

In very dense bone during placement, the implant may need to be turned in 1 rotation increments with a 1 minute rest between each. This is to allow the dense bone to recover or recoil from the advancing self-tapping implant to prevent bone overcompression or implant fracture. An incision may or may not be necessary. Adequate attached gingiva is appropriate for these implants.

Very small implants may be used in conjunction with standard diameter (3.75–4.1 mm) implants to support a fixed prosthesis where there is an area of thin bone next to or near an area that will accept a standard diameter implant.

The cost of very small diameter implants can about 20% to 50% less than standard diameter implants making treatment less expensive.

Placing very small diameter implants requires careful osseous, gingival, esthetic, and occlusal analysis but very small diameter implants can be considered for use in a very selective number of sites.

If during the osteotomy of a small diameter implant there is an unforeseen bone density or site inadequacy, the use of a slightly larger diameter implant that is able to attain better initial stability remains an option, given adequate space and density or bone manipulation techniques such as ridge expansion or splitting. Consequently, it may be better to have a bias to placement of smaller diameter than

larger diameter implants. Larger diameter implants may be better suited in the esthetic zone to provide for the emergence profile of the crown. However, in anterior compromised sites, especially where there has been site length attenuation, smaller diameter implants may be appropriate when the occlusal forces can be minimized or eliminated.

When placing very small implants, it is the experience of this author that placement torque should not exceed 50 Ncm. Over compression of the bone may lead to osseous compression necrosis and the implant may fail to integrate. Additionally, higher torque forces may cause fracture of the implant shaft.

Although the forces of occlusion are less in the anterior jaws than in the posterior, chronically directed, off axial, forces may cause implant or component fatigue fracture or loss of integration of an implant. The prosthesis can be relieved in centric occlusion so as to avoid the chronic occlusal contact (cyclic loading) and reduce the occlusal force impact.

Teeth may intrude as much as 250 μm whereas an osseointegrated implant may intrude as much as 7 μm in bone. As the natural teeth functionally move into bone, the opposing teeth may directly contact the prosthesis and the discrepancy of movement may produce a loss of integration of the bone to implant contact and result in failure of the implant. There may be room for error in that the opposing teeth also intrude giving the prosthetic implant less of a firm force against it. If the teeth adjacent to the supporting implant intrude up to 250 μm and then contact is made with the opposing teeth and they can intrude 250 μm as well, then the sum of these intrusions may be as much as 500 μm before a solid contact is made. Should fixed prostheses be constructed shy of occlusion by 0.5 mm? Probably not, but the exact amount of the relief, at this point in the technology, is an unanswered question. Additionally, very small diameter implants may be prone to metal fatigue fracture if the prosthesis is placed in an inappropriate occlusal scheme. There is no evidence-based implant specific concept of occlusion but metal fatigue may be an issue.^{11,12}

Tarnow *et al*¹³ determined that there is a 1.4 mm circumferential bone crest resorption about implants. This may mean that the appropriate implant site width is the diameter of the proposed implant plus the 1.4 mm circumferential bone resorption at each perspective. Thus, a 4.0 mm diameter implant would require: 4.0 mm + 1.4 mm (facially) + 1.4 mm (lingually) = 6.8 mm bone width. Very small 2 mm diameter implants do not seem to demonstrate this phenomenon. Because of this information smaller diameter implants may be more appropriate for many compromised sites.¹⁴

Patients who present with a complete maxillary denture with remaining only mandibular anterior teeth may benefit from this modality. These patients usually have thin atrophic posterior residual ridges that will not accept a standard diameter implant without osseous grafting. Because the forces generated by these complete denture patients is generally less than with natural dentition, very small diameter implants may very successfully support fixed posterior splinted partial dentures. This treatment may prevent these patients from developing combination syndrome, where there is supereruption of the remaining anterior teeth, fibrous replacement of the anterior maxilla and continued atrophy of the posterior edentulous ridges.

Knowledge of the available array of implant sizes is an asset for the implantologist. Sites accepting these small diameter implants in this case series were perceived to be of denser bone types I, II and III. There will be an increased per square millimeter force exerted on the supporting bone by the implants during function. So, multiple implants may be necessary to dissipate forces among the implants to minimize osseous stress.

Posterior prosthetic teeth were made in these cases with rounded cusps and narrow occlusal tables that present a small area for functional occlusal impact and to minimize off-axial forces. Zinc phosphate cement (Flecks) was used to lute all cases listed but resin modified glass ionomer or resin cement can also be used.

Because these implants are not used with conventional osteotomy

drills but with very thin drills. If the thin ridge is split and expanded with a #15 scalpel the appropriate bone width for a proposed site may be the sum of postoperative peri-implant bone crest resorption of 1.4 mm at facial and lingual, or 2.8 mm. However, there may not be as much resorption as a standard sized implant and the osseous resorption of 1.4 mm seems to not apply to mini implants. This type of osseous crest resorption may not be prevalent with these implants possibly because of less impedance of the blood supply. So a very narrower ridge may successfully accommodate the mini implant.

Very small diameter implants may be used for single crowns where occlusal accommodations are made so that there are no occlusal contacts. Additionally, very small diameter implants may be used to support fixed partial dentures in multiples or in tandem with larger diameter implants. Occlusal schemes can be designed with contact only in centric and no excursive contacts.

Because the surgical placement of mini implants is much less traumatic as compared with standard sized implants they may be useful for medically compromised or elderly patients.

Complications and Caveats

There are caveats and complications that need to be considered when placing very small diameter implants. Overcompression of the bone can result in a failure to osseointegrate. However, it has been this author's experience that, with the use of a torque controlled handpiece, with less than 50 Ncm insertion torque, this problem has not been seen. Manual ratchet placement use, where the placement torque is unknown, may result in osseous overcompression and loss of the implant. Additionally, the use of excessive placement torque may fracture the narrow implant.

The osteotomy drill is very thin and may fracture during the osteotomy. Careful drill manipulation is a concern. If this occurs, multiple radiographic views, including computerized tomography, may be taken to exactly ascertain the drill fragment's position. Retrieval by osseous exploration is not a recommended course of action. Once the drill position is radiographically ascertained, the piece may then be retrieved.

Metal fatigue of the implant coronas may be a long-term result of an "under-engineered" or a high cusped fixed partial denture. That is, installation of too few implants may not resist chronic occlusal forces, cyclic loading, and cause fracture of the narrow implant coronal shaft. Additionally, placing high esthetic cusps may allow increased lateral or off-axial forces to be applied and thus fatigue the implant shaft.

CONCLUSIONS

In highly selected edentulous sites very small diameter, or mini, implants may be used to support fixed prostheses.

Disclosure

The author claims to have no financial interest, directly or indirectly, in any entity that is commercially related to the products mentioned in this article.

REFERENCES

1. Esposito M, Grusovin MG, Coulthard P, et al. The efficacy of various bone augmentation procedures for dental implants: A Cochrane systematic review of randomized controlled clinical trials. *Int J Oral Maxillofac Implants*. 2006;21:696-710.
2. Kanie T, Nagata M, Ban S. Comparison of the mechanical properties of 2 prosthetic mini-implants. *Implant Dent*. 2004;13:251-256.
3. Ahn MR, Choi JH, Sohn DS. Immediate loading with mini dental implants in

the fully edentulous mandible. *Implant Dent*. 2004;13:367-372.

4. Fritz U, Diedrich P, Kinzinger G, et al. The anchorage quality of mini-implants towards translatory and extrusive forces. *J Orofac Orthop*. 2003;64:293-304.

5. Flanagan D. Implant-supported fixed prosthetic treatment using very small-diameter implants: A case report. *J Oral Implantol*. 2006;32:34-37.

6. Romeo E, Lops D, Amorfini L, et al. Clinical and radiographic evaluation of small-diameter (3.3-mm) implants followed for 1-7 years: A longitudinal study. *Clin Oral Implants Res*. 2006;17:139-148.

7. Mazor Z, Steigmann M, Leshem R, et al. Mini-implants to reconstruct missing teeth in severe ridge deficiency and small interdental space: A 5 year case series. *Implant Dent*. 2004;13:336-341.

8. Cosme DC, Baldisserotto SM, Canabarro SA, et al. Bruxism and voluntary bite force in young dentate adults. *Int J Prosthodont*. 2005;18:328-332.

9. Vigolo P, Givani A, Majzoub Z, et al. Clinical evaluation of small-diameter implants in single-tooth and multiple-implant restorations: A 7-year retrospective study. *Int J Oral Maxillofac Implants*. 2004;19:703-709.

10. Vigolo P, Givani A. Clinical evaluation of single-tooth mini-implant restorations: A five-year retrospective study. *J Prosthet Dent*. 2000;84:50-54.

11. Kim Y, Oh TJ, Misch CE, et al. Occlusal considerations in implant therapy: Clinical guidelines with biomechanical rationale. *Clin Oral Implants Res*. 2005;16:26-35.

12. Davarpanah M, Martinez H, Tecucianu JF, et al. Small-diameter implants: Indications and contraindications. *J Esthet Dent*. 2000;12:186-194.

13. Tarnow D, Elian N, Fletcher P, et al. Vertical distance from the crest of bone to the height of the interproximal papilla between adjacent implants. *J Periodontol*. 2003;74:1785-1788.

14. Comfort MB, Chu FC, Chai J, et al. A 5-year prospective study on small diameter screw-shaped oral implants. *J Oral Rehabil*. 2005;32:341-345.

Reprint requests and correspondence to:

Dennis Flanagan, DDS
1671 West Main St.
Willimantic, CT 06226
Phone: 860-456-3153
Fax: 860-456-8759
E-mail: dffdds@charter.net

GERMAN / DEUTSCH

AUTOR: Dennis Flanagan, DDS. Korrespondenz an: Dennis Flanagan DDS, 1671 West Main St., Willimantic, Conn. 06226. Telefon: 860-456-3153, Fax: 860-456-8759, eMail: dffdds@charter.net

Durch Zahnimplantate mit sehr geringem Durchmesser gestützte feste Teilprothesen und -überkronungen für beeinträchtigte Implantationsbereiche

ZUSAMMENFASSUNG: Zahnimplantate von sehr geringem Durchmesser (1.8–3.3 mm) können erfolgreich dazu eingesetzt werden, feste Teilprothesen in den zahnlosen Bereichen von beeinträchtigtem Knochengewebe mit zu geringer Breite oder Länge zu unterstützen. Sehr kleine Implantate können in speziell ausgewählten Bereichen erfolgreichen Einsatz finden, vorausgesetzt, Knochendichte und Knochenvolumen reichen für eine sofortige Stabilisierung des Implantats aus. Entsprechend ausreichendes bzw. aufbaubares Zahnfleisch kann hierbei eine Voraussetzung darstellen. Ein Implantat mit kleinem Durchmesser stellt ein geringeres Hindernis für eine Gefäßbildung dar. Außerdem sind gegenüber normal großen Implantaten der Kontakt zur unverletzten Haut sowie die Gefahr einer Knochenluxation geringer. Bei Implantationsstellen im hinteren Mundraum bietet eine abgerundete und schmale Zahnprothetik kleine okklusale Brettchen, um darüber die in Achsenrichtung wirkenden sowie entgegen der Achse laufenden Kräfte zu minimieren. Vielfach gespannte Implantate können erforderlich sein, um eine durch die zyklische Belastung hervorgerufene Metallermüdung möglichst gering zu halten. Wiederherstellungslösungen mit Unterstützung durch Mini-Implantate im vorderen Kieferbereich benötigen eventuell eine okklusale Entlastung, um die Auswirkungen einer zyklischen Belastung zu minimieren.

SCHLÜSSELWÖRTER: Mini-Implantat, okklusales Schema, Knochendichte, Knochenkamm.

SPANISH / ESPAÑOL

AUTOR: Dennis Flanagan DDS. Correspondencia a: Dennis Flanagan DDS, 1671 West Main St., Willimantic, Conn. 06226. Teléfono: 860-456-3153, Fax: 860-456-8759, Correo electrónico: dffdds@charter.net

Dentaduras parciales fijas y coronas apoyadas por implantes dentales de diámetro muy pequeño en lugares problemáticos

ABSTRACTO: Los implantes dentales de muy pequeño tamaño (1.8–3.3mm) pueden usarse con éxito para apoyar dentaduras parciales fijas en lugares desdentados donde el ancho o largo del hueso se ha visto afectado negativamente. Los implantes muy pequeños pueden usarse con éxito en

lugares altamente selectos donde existe una densidad del hueso y volumen óseo adecuados para ofrecer una estabilidad inmediata del implante. También podría requerirse una encía adecuada o aumentable conectada. Un implante de diámetro pequeño presenta menos obstáculos para la angiogénesis y existe menos exposición percutánea y desplazamiento del hueso comparado con implantes de tamaño normal. En lugares posteriores, dientes postizos redondeados y angostos presentan pequeñas tablas oclusales para reducir las fuerzas dirigidas axiales o no axiales. Múltiples implantes con tablillas podrían ser necesarios para reducir la fatiga del metal de la carga cíclica. Las restauraciones anteriores apoyadas por miniimplantes podrían necesitar un alivio oclusal para reducir los efectos de la carga cíclica.

PALABRAS CLAVES: Miniimplante, esquema oclusal, densidad del hueso, cresta del hueso.

PORTUGUESE / PORTUGUÊS

AUTOR: Dennis Flanagan, Cirurgião-Dentista. Correspondência para: Dennis Flanagan DDS, 1671 West Main St., Willimantic, Conn. 0622. Telefone: 860-456-3153, Fax: 860-456-8759, e-mail: dffdds@charter.net

Dentaduras Parciais Fijas e Coroas Suportadas por Implantes Dentários de Diâmetro Muito Pequeno em Locais Comprometidos

RESUMO: Implantes dentários de diâmetro muito pequeno (1.8–3.3mm) podem ser usados com sucesso para suportar dentaduras parciais fixas em locais desdentados de largura ou comprimento de osso comprometido. Implantes muito pequenos podem ser usados com sucesso em locais altamente selecionados onde haja adequada densidade de osso e volume de osso para imediata estabilidade do implante. Gengiva anexada adequada ou aumentável pode ser um requisito. Um implante de diâmetro pequeno apresenta menos de um obstáculo para a angiogênese e há menos exposição percutânea e deslocamento do osso em comparação com implantes de tamanho padrão. Em locais posteriores, dentes protéticos arredondados e estreitos apresentam pequenas tabelas oclusais para minimizar forças dirigidas axiais e extra-axiais. Implantes esplintados múltiplos talvez sejam necessários para a fadiga do metal da carga cíclica. Restaurações anteriores suportadas por mini-implantes talvez precisem de relevo oclusal para minimizar os efeitos da carga cíclica.

PALAVRAS-CHAVE: Mini-implante, esquema oclusal, densidade do osso, rebordo do osso.

RUSSIAN / РУССКИЙ

АВТОР: Dennis Flanagan, доктор стоматологии. Адрес для корреспонденции: Dennis Flanagan DDS, 1671 West

Main St., Willimantic, Conn. 06226. Телефон: 860-456-3153, Факс: 860-456-8759, Адрес электронной почты: dffdds@charter.net

Частичный несъемный зубной протез и коронки с опорой на зубные имплантаты очень малого диаметра в местах аномального расположения зубов

РЕЗЮМЕ. Зубные имплантаты очень малого диаметра (1,8–3,3 мм) могут успешно использоваться как опора для частичного несъемного зубного протеза на участках отсутствия зубов с аномальной шириной или длиной кости. Очень маленькие имплантаты могут успешно использоваться на тщательно отобранных участках с адекватной плотностью и объемом кости для первичной стабилизации имплантата. Условием для этого может быть адекватная или требующая наращивания зона прикрепленной десны. Имплантат малого диаметра меньше препятствует ангиогенезу, а чрескожное воздействие и изменение кости меньше по сравнению с имплантатами стандартного размера. На участках задней зубной дуги закругленные или узкие искусственные зубы представляют собой маленькие окклюзионные поля, что минимизирует аксиально и неаксиально направленные силы. Может понадобиться составной шинированный имплантат для сведения к минимуму усталости металла от циклической нагрузки. Для пломб передней группы зубов с опорой на миниимплантаты может потребоваться ослабление окклюзии для минимизации действия циклической нагрузки.

JAPANESE / 日本語

弱化した部位で微小直径デンタルインプラントをサポートに使用したフィクスド・パーシャルデンチャーとクラウン

共同研究者氏名: デニス・フラナガン (Dennis Flanagan) DDS

研究概要: 骨の幅または長さが不十分な無歯部位でフィクスド・パーシャルデンチャーをサポートする場合、微小直径(1.8-3.3mm)デンタルインプラントの使用が功を奏することがある。即時インプラント安定性確保に必要なだけの骨密度と骨量がある限定部位では微小インプラントを使用すると成功する可能性がある。これには十分な、あるいは補修可能な附着歯肉を必須条件とする。微小直径インプラントはスタンダードサイズインプラントと比較して血管新生に対して障害を生じる可能性が少なく、また経皮露出や骨転移も少ない。後部では丸みをおび幅の狭い義歯が axial ならびに off-axial の直接負荷を最小限に抑える小面積の occlusal table を示す。Cyclic loading で起る金属疲労を最小限に抑えるには multiple splinted インプラントが必要となる場合もある。ミニインプラントでサポートする前歯補綴には cyclic loading の影響を最小限に抑えるために咬合緩和の必要性もある。

キーワード: ミニインプラント, 咬合スキーム, 骨密度, 骨梁

ご質問の宛先: Dennis Flanagan DDS, 1671 West Main St., Willimantic, Conn. 06226
電話: 860-456-3153 FAX: 860-456-8759 電子メール: dffdds@charter.net

КЛЮЧЕВЫЕ СЛОВА: миниимплантат, окклюзионная схема, плотность кости, костный гребень.

TURKISH / TÜRKÇE

YAZAR: Diş Hekimi Dennis Flanagan. *Yazışma için: Dennis Flanagan DDS, 1671 West Main St., Willimantic, Conn. 06226 ABD. Telefon: 860-456-3153, Faks: 860-456-8759. eposta: dffdds@charter.net*

Tehlikeye Düşmüş Yerlerde Çok Küçük Çaplı Dental İmplantlar Tarafından Desteklenen Sabit Kısmi Protez Dişler ve Kronlar

ÖZET: Çok küçük çaplı (1.8–3.3 mm) dental implantlar, kemik genişliğinin veya uzunluğunun tehlikeye düşmüş olduğu dişsiz yerlerde sabit kısmi protez dişleri desteklemek üzere başarıyla kullanılabilir. Hemen yüklenen implantın stabilitesi için yeterli kemik yoğunluğu ve kemik hacmi olan titizlikle seçilmiş yerlerde çok küçük implantlar başarıyla uygulanabilir. Yeterli veya ogmantasyon yapılabilecek diş eti bunun için bir koşul olabilir. Küçük çaplı bir implant, anjiogenez için daha az bir engel oluşturur ve standart boyutlu implantlara göre perkütan açıklık ve kemik deplasmanı daha az düzeydedir. Posterior alanlardaki yuvarlanmış ve dar protez dişler, aksiyal ve off-aksiyal yöneltmiş güçleri en aza indirmek için küçük oklüzyon düzeyleri teşkil eder. Çevrimsel yüklemenin yol açtığı metal yorgunluğunu en aza indirmek için splintlenmiş multipl implantlar gerekebilir. Mini implantlar ile desteklenen anterior restorasyonlarda çevrimsel yüklemenin etkilerini en aza indirmek için oklüzyon rahatlaması sağlamak gereksinimi olabilir.

ANAHTAR KELİMELER: Mini implant, oklüzyon planı, kemik yoğunluğu, kemik kreti

受損部位極小直徑牙科植體支撐的固定式局部義齒和牙冠

作者：Dennis Flanagan DDS

摘要：極小直徑 (1.8-3.3mm) 植體可成功運用在骨質寬度或長度受損的缺牙部位，以支撐固定式局部義齒。極小植體可以成功應用在高度選擇性部位，此部位含足夠的骨質密度及骨量，可提供立即植體穩定性。可能需有足夠的附連齒齦或擴大附連齒齦。和標準尺寸植體比較，小直徑植體出現的血管新生障礙較少，同時經皮膚暴露和骨頭移位也較少。在後面部位，圓形和窄小的贗復齒出現小的咬合檯面，讓軸線及軸線外的力量降到最低。多夾板植體可能需要將因反覆負荷所致的金屬疲勞降到最低。迷你植體支撐的前面重整可能需要咬合緩壓，將反覆負荷的影響降到最低。

關鍵字：迷你植體、咬合模式、骨質密度、骨脊

通訊方式：Dennis Flanagan DDS, 1671 West Main St., Willimantic, Conn. 06226

電話：860-456-3153 傳真：860-456-8759 電郵信箱：dffdds@charter.net

절충 부위에 매우 적은 지름의 치과용 임플란트로 지지된 고정된 부분 의치 및 치관

저자: 데니스 플라나간(Dennis Flanagan) 구강외과 의사(DDS)

초록: 매우 작은(1.8-3.3mm) 치과용 임플란트는 절충된 골 너비나 길이의 무치 부위에 고정된 부분 의치를 지지하는데 성공적으로 사용될 수 있다. 또한 임플란트를 즉시 안정할 수 있는 적절한 골밀도와 골용적을 보이는 고도의 선택 부위에 성공적으로 사용될 수 있다. 적절하거나 확장 가능한 부착 잇몸이 필요하다. 지름이 작은 임플란트는 일반 임플란트와 비교하여 혈관형성에 대한 장애가 적고 경피 노출과 골치환도 적다. 후측에서 둥글고 좁은 인공 치아는 축 및 축 이탈 지정력을 최소화하기 위해 작은 교합상을 보인다. 여러 부목을 덴 임플란트는 반복하중으로 인한 금속 피로도의 최소화에 필요하다. 소형 임플란트로 지지된 전방 복원은 반복하중의 효과를 최소화하기 위해 교합 이완이 필요할 수 있다.

키워드: 소형 임플란트, 교합 양상, 골밀도, 치조제

연락처: 데니스 플라나간(Dennis Flanagan) 구강외과 의사(DDS), 1671 West Main St., Willimantic, Conn. 06226

전화: 860-456-3153 팩스: 860-456-8759 이메일: dffdds@charter.net