

See discussions, stats, and author profiles for this publication at: <https://www.researchgate.net/publication/8208219>

# Clinical evaluation of small-diameter implants in single-tooth and multiple-implant restorations: A 7-year retrospective study

Article in *The International journal of oral & maxillofacial implants* · September 2004

Source: PubMed

---

CITATIONS

68

---

READS

200

4 authors, including:



[Paolo Vigolo](#)

University of Padova

39 PUBLICATIONS 1,169 CITATIONS

[SEE PROFILE](#)



[Zeina AK Majzoub](#)

Lebanese University

34 PUBLICATIONS 1,519 CITATIONS

[SEE PROFILE](#)

# Clinical Evaluation of Small-Diameter Implants in Single-Tooth and Multiple-Implant Restorations: A 7-year Retrospective Study

Paolo Vigolo, Dr Odont, MScD<sup>1</sup>/Andrea Givani, MD, DDS<sup>2</sup>/Zeina Majzoub, DCD, DMD, MScD<sup>3</sup>/  
Giampiero Cordioli, MD, DDS<sup>4</sup>

**Purpose:** Placement of small-diameter implants often provides a solution to space-related problems in implant restoration. This 7-year retrospective study presents results from 192 small-diameter implants placed in 165 patients from 1992 to 1996. **Materials and Methods:** The dental records of each patient were reviewed. The implants, which were either 2.9 mm or 3.25 mm in diameter, were placed by 2 different surgeons. All prosthetic appliances were fabricated by the same prosthodontist. Ninety-four implants supported single-tooth cemented restorations; the remaining 98 implants supported cemented or screw-retained partial prostheses. **Results:** The total implant survival rate was 95.3%. Four implants were lost at second-stage surgery, and 5 more were lost after loading. **Discussion:** Small-diameter implants demonstrated a survival rate similar to those reported in previous studies of standard-size implants. **Conclusions:** The results suggest that small-diameter implants can be successfully included in implant treatment. They may be preferable in cases where space is limited. *INT J ORAL MAXILLOFAC IMPLANTS* 2004;19:703-709

**Key words:** partial prostheses, single-tooth prostheses, small-diameter implants

In implant dentistry, the use of standard-size or wide-diameter implants is generally recommended to ensure adequate bone-to-implant contact.<sup>1</sup> Occasionally, the space available may be insufficient for the placement of implants of such dimensions. When the space available is inadequate for a standard or wide-diameter implant, use of a small-diameter implant can be an acceptable solution.

From the data available in the literature, standard-size endosseous implants have been used with consistent results in the rehabilitation of completely

and partially edentulous arches and single-tooth gaps.<sup>2-20</sup> With regard to the rehabilitation of completely edentulous arches, Ahlqvist and associates<sup>6</sup> studied osseointegrated implants in 50 edentulous jaws during a 2-year observation period. The implant survival rate was 89% in maxillae and 97% in mandibles. Zarb and Schmitt<sup>7</sup> studied prospectively the 5- to 10-year results of edentulous patients treated with implant-supported fixed partial dentures. At the end of the observation period, 88.32% of the implants remained osseointegrated. Forty-three fixed prostheses and 5 overdentures were supported by 85.04% of these implants.

Regarding partially edentulous patients, van Steenberghe<sup>10</sup> investigated the prognosis of osseointegrated implants in partially edentulous jaws in a multicenter retrospective study. The observation time varied between 6 and 36 months after prosthetic reconstruction. The success rates for individual implants were 87% in the maxilla and 2% in the mandible. Zarb and Schmitt<sup>11</sup> reported the results of 105 osseointegrated implants placed in the posterior zones in 46 partially edentulous patients.

<sup>1</sup>Assistant Professor, Department of Clinical Odontostomatology, University of Padova, Institute of Clinical Dentistry, Padova, Italy.

<sup>2</sup>Private Practice, Vicenza, Italy.

<sup>3</sup>Professor, Department of Periodontology, Lebanese University, School of Dentistry, Beirut, Lebanon.

<sup>4</sup>Professor and Chairman, Department of Clinical Odontostomatology, University of Padova, Institute of Clinical Dentistry, Padova, Italy.

**Correspondence to:** Dr Paolo Vigolo, Via Vecchia Ferriera, 13, 36100 Vicenza, Italy. Fax: 39 044 496 4545. E-mail: paolovigolo@virgilio.it

One hundred five implants were placed in 46 edentulous areas in 35 patients. After periods of loaded service ranging from 2.6 to 7.4 years (mean 5.2 years), 40 of the 41 implants placed in maxillae (97.6%) remained in function, and 59 of the 64 placed in mandibles (92.2%) remained in function, with an overall implant survival rate of 94.3%. Zarb and Schmitt<sup>12</sup> also reported an average success rate of 91.5% for implants placed in the anterior region of partially edentulous maxillae and mandibles.

With regard to single-tooth restorations, Cordioli and colleagues<sup>2</sup> reported the clinical experience of 47 patients rehabilitated with a single-tooth restoration. The total implant survival rate was 94.4%. Engquist and associates<sup>18</sup> evaluated the outcome of single-tooth restorations supported by Brånemark System implants (Nobel Biocare, Göteborg, Sweden) placed between 1984 and 1989; the overall survival rate was 97.6%. McMillan and coworkers<sup>20</sup> investigated the nature, timing, and frequency of complications associated with single-tooth implant therapy in a dental hospital and 2 dental offices. They reported an implant survival rate of 96%.

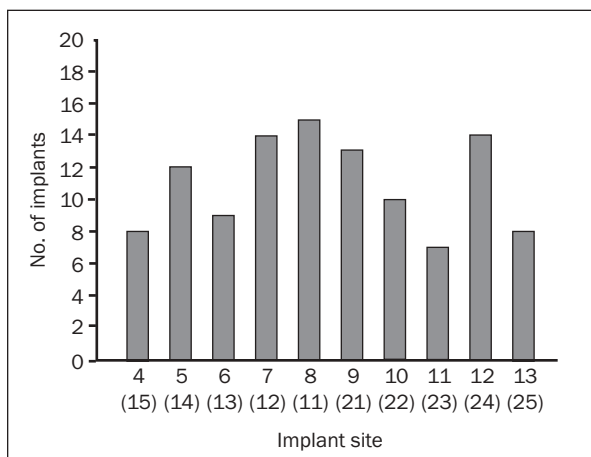
The available literature provides few laboratory-based articles that show the results accomplished using implants of different diameters. Ivanoff and coworkers<sup>21</sup> studied the influence of diameter on the integration of titanium screw-shaped implants in rabbit tibiae by means of removal torque measurements and histomorphometry. They inserted implants 3.0, 3.75, 5.0, and 6.0 mm in diameter and 6.0 mm long through 1 cortical layer in the tibial metaphyses of 9 rabbits and allowed them to heal for 12 weeks. The implants were then unscrewed with a torque gauge, and the peak torque required to shear off the implants was recorded. The biomechanical tests showed a statistically significant increase in removal torque with increasing implant diameter.

Two studies have questioned the importance of implant diameter. In one study,<sup>22</sup> the effects of diameter and length on the pull-out force required to extract hydroxyapatite-coated implants from dog alveolar bone were examined. After 15 weeks of integration, implants 3.0, 3.3, and 4.0 mm in diameter and 4, 8, and 15 mm in length were pulled. The results of this study showed that the pull-out force correlated strongly to implant length but not to diameter. The other study<sup>23</sup> compared the pull-out resistance of small- and large-diameter (3.25- and 4.25-mm) dental implants placed in the mandibles of 5 embalmed humans and the relationship between pullout resistance and bone density. The maximum pull-out force required for the large-diameter implants was 15% greater than that required for the small-diameter implants, but the difference was not

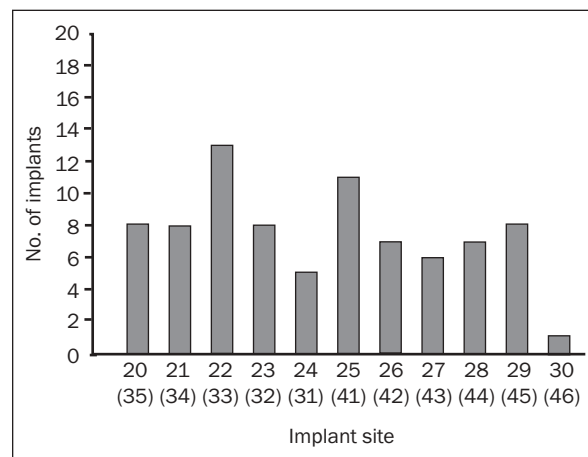
statistically significant. In the same study a significant positive correlation between pull-out resistance and bone density was noted for both large-diameter ( $P < .05$ ) and small-diameter implants ( $P < .01$ ). However, the real clinical significance of torque and pull-out tests remains controversial.

Davarpanah and associates<sup>24</sup> suggested that small-diameter implants are indicated in specific clinical situations (eg, where there is reduced interdental bone or a thin alveolar crest, for the replacement of teeth with small cervical diameter). In a clinical investigation, Polizzi and coworkers<sup>25</sup> used 3.0-mm-wide implants to support 30 single maxillary and mandibular incisors in 21 patients. The implants were in function for 3 to 7 years, and 29 were still stable at the end of the study. The overall success rate was 96.7%. In a previous study, Vigolo and Givani<sup>26</sup> summarized 5 years of clinical data on a group of patients treated using 2.9-mm-wide mini-implants. The results achieved by the mini-implant rehabilitations were similar to those reported for standard single-tooth implant restorations. The overall implant survival rate was 94.2%. Andersen and colleagues<sup>27</sup> compared the success rate and marginal bone resorption of small-diameter self-tapping implants placed in minimal bone volume with standard-diameter self-tapping implants placed in an alveolar process with good dimensions. Fifty-five patients were included in the study; 27 patients received 28 standard-diameter (3.75-mm) implants, and 28 patients received 32 small-diameter (3.25-mm) implants to replace central and/or lateral incisors in the maxilla. In both groups, marginal bone loss followed the same pattern, and a mean radiographic bone loss of 0.4 mm was recorded from the first examination to the last. The use of small-diameter implants has been advocated in orthodontic treatment.<sup>28</sup> Gedrange and associates<sup>29</sup> tested the effects of bite and orthodontic forces exerted on 3 types of endosseous titanium implants (all 9 mm in length and 3.3 mm in diameter). All implant types investigated showed good biomechanical properties.

Hallman<sup>30</sup> evaluated the use of reduced-diameter implants as an alternative to bone grafting for the treatment of patients with severely resorbed maxillae. Forty patients (25 women and 15 men; mean age 57 years, range 19 to 86 years) with insufficient bone volume for the placement of standard-size implants in the maxilla, 31 of whom were completely edentulous, were treated with 3.3-mm-wide ITI titanium plasma-sprayed solid-screw implants (Straumann, Waldenburg, Switzerland). Preoperative radiographic examination showed that in all cases, the height of the alveolar crest was less than 10 mm



**Fig 1a** Distribution of maxillary small-diameter implants.



**Fig 1b** Distribution of mandibular small-diameter implants.

where the width was 4 mm. A total of 182 implants either 8 or 12 mm in length were placed. Three patients received overdentures, and 3 others received single-crown restorations; the remaining patients were treated with fixed prostheses. One 8-mm-long implant was lost 1 month after placement. The survival rate was 99.4% after 1 year of loading. Four implants with peri-implantitis were successfully treated and 1 implant was a “sleeper” because of malposition; the cumulative success rate was 96.4%.

Zinsli and coworkers<sup>31</sup> evaluated 2-part ITI implants (full-body screws 3.3 mm in diameter; Straumann) in a prospective clinical study. One hundred forty-nine partially or completely edentulous patients received a total of 298 implants over a 10-year period. After a standard healing period (3 to 6 months), the implants were restored with fixed restorations such as single crowns, fixed partial or complete prostheses, or overdentures. Complete prostheses or overdentures in the edentulous jaw were the predominant types of restoration. The cumulative 5-year implant survival rate was 98.7%; after 6 years, it was 96.6%. The authors concluded that the success of 3.3-mm ITI implants appears to be predictable if clinical guidelines are followed and appropriate prosthetic restorations are provided. However, fatigue fracture can occur after a long period of function.

The aim of this study was to collect and summarize 7 years of clinical data on a group of patients treated using small-diameter implants for single-tooth and multiple-tooth restorations, both in a private clinic and in a university environment.

## MATERIALS AND METHODS

Between 1992 and 1996, 683 patients were offered implant treatment in a private office setting and at

the Implant Center of the Institute of Clinical Dentistry of the University of Padova (Italy). A total of 3,227 implants were placed. All small-diameter implants placed in the timeframe under consideration were included in the study. During the inclusion period, 165 patients (101 women and 64 men ranging from 17 to 74 years old; mean age 39 years) each received at least 1 small-diameter implant and prosthesis to replace their missing teeth. All patients in the sample group were in good health. All 165 returned for recall, and all have been included in the initial and final data.

A total of 192 small-diameter implants (3i/ Implant Innovations, Palm Beach Gardens, FL), 100 of which were 2.9 mm wide and 92 of which were 3.25 mm wide, were positioned following a conventional 2-stage surgical technique (Fig 1). Small-diameter implants were chosen where space limitations prevented the use of wider ones. Surgical templates were used to decrease the risk of damaging the adjacent teeth and to compensate for difficulties in the prosthetic phase caused by poor positioning of the implant. If an implant had to be placed in an extraction site in an esthetic area, a 2-month waiting period was used to allow the soft tissues to heal before implant placement. Ninety-two implants were placed in type 1 bone, 52 in type 2 bone, 34 in type 3 bone, and 14 in type 4 bone.<sup>32</sup> Ninety-four small-diameter implants were used for cemented single-tooth restorations; the remaining 98 implants were used in combination with standard-size implants to support partial prostheses. Thirty-two implants were combined with standard-diameter implants to support fixed cemented partial prostheses, and 66 supported fixed screw-retained prostheses. The number of small-diameter implants used is summarized in Table 1.

The 126 small-diameter implants that supported cement-retained restorations were restored with

**Table 1 Length and Diameter of Small-Diameter Implants Used**

Length (mm)	Diameter (mm)	No. of implants
8.5	2.90	8
10.0	2.90	30
13.0	2.90	42
15.0	2.90	20
8.5	3.25	2
10.0	3.25	21
11.5	3.25	37
13.0	3.25	22
15.0	3.25	10

UCLA abutments directly engaged on the implant heads. Gold machined UCLA abutments (GUCA3 for the 2.9-mm-wide implants, MUCG1 for the 3.25-mm-wide implants; 3i/Implant Innovations) were used. Provisional resin restorations were fabricated, secured to the posts with temporary cement (Temp Bond NE; Kerr Italia, Scafati, Italy), and left in for a 2-month period. The use of provisional prostheses enhanced healing of the peri-implant soft tissues and also permitted evaluation of the occlusion and alteration of both the static and dynamic occlusal contacts. After this phase, regular porcelain-fused-to-metal definitive crowns and fixed partial restorations with porcelain occlusal surfaces were fabricated for 82 of these implants. Esthetic factors were of less importance for the remaining 44 implants; thus, resin-and-gold crowns and fixed partial restorations with gold occlusal surfaces were fabricated. The occlusal surfaces of the restorations were designed to avoid premature contact during lateral and protrusive movements. All definitive restorations were cemented with Temp Bond NE temporary cement.

Sixty-six of the small-diameter implants were joined to standard-size implants to support screw-retained restorations. Provisional restorations were not fabricated in these cases. Gold machined UCLA abutments (3i/Implant Innovations) were used; the metal structures were waxed and cast using a noble alloy following standard laboratory procedures. After ceramic application, the definitive restorations were screwed onto the implants using a torque wrench calibrated at 30 Ncm (Torque Drive CATDO; 3i/Implant Innovations). The occlusal surfaces of the restorations were designed to avoid premature contact during lateral and protrusive movements. The screw access holes on the occlusal surfaces of the partial prostheses were closed with composite resin (Tetric Ceram; Ivoclar Vivadent, Schaan, Lichtenstein) 1 month after prosthesis delivery.

Following prosthetic treatment, the patients were seen for follow-up every 3 months during the first year and every 6 months in subsequent years. All the patients regularly returned to the office or to the university clinic for recall. Implant survival was based on the following criteria<sup>3</sup>:

- Absence of mobility (mobile implants were removed)
- Absence of painful symptoms or paresthesia
- Absence of peri-implant radiolucency
- Absence of progressive marginal bone loss

Seven years after implant placement, at the last follow-up appointment, all patients were seen and the presence or absence of supragingival plaque, presence or absence of gingival inflammation, bleeding on probing, amount of keratinized gingiva around the abutment, and probing depth from the gingival margin were recorded based on peri-implant mucosal response at the 4 surfaces. All cemented crowns and partial prostheses were carefully removed using pliers (GC Removal Pliers, K. Y. Type; GC Corporation, Tokyo, Japan) to avoid damaging them. The custom posts and screw-type prostheses were unscrewed to allow the measurement of the sulcus depth. A periodontal probe was used to record the length from the marginal gingiva to the head of the implant. Intraoral radiographic examinations were performed using the paralleling technique and an adjusted film-holding device as suggested in previous studies.<sup>2,33</sup> The radiographic films were observed using a 5× magnifying lens, which permitted the measurement of marginal bone resorption with an accuracy of ± 0.3 mm. Occlusal relationships and all prosthetic complications were recorded. All evaluations were accomplished by the same prosthodontist who carried out the prosthetic procedures.

## RESULTS

Four implants (10 mm in length) failed during the second surgical phase. Two of these implants had been placed in type 4 bone in first premolar sites in the maxilla in a 52-year-old woman. This patient was restored with 2 partial ceramometal 3-unit fixed prostheses connecting the second premolars to the canines. The other 2 failed implants had been placed in a mandibular incisal site in a 62-year-old man who was a heavy smoker. This patient was also treated with a conventional ceramometal prosthesis supported by his proximal natural teeth.

Five more implants were lost after loading. One implant (13 mm in length), which had been placed

**Table 2 Prosthetic Complications Observed in the 165 Patients Treated with Small-Diameter Implants**

Sex	Age	Implant location	Implant size (mm)	Prosthesis type	Retention	Time elapsed (mo)*	Complication
F	25	Mandibular left lateral incisor	3.25 × 13	STR	Cemented	3	Lost implant
F	48	Maxillary right first premolar	3.25 × 10	MIR	Screw-retained	3	Lost implant
		Maxillary right second premolar					
		Maxillary left first premolar					
		Maxillary left second premolar					
M	37	Maxillary right canine	3.25 × 15	STR	Screw-retained	6	Loose screw
						12	Loose screw
M	25	Maxillary right canine	2.9 × 15	MIR	Cemented	6	Provisional prosthesis fracture
M	45	Maxillary left second premolar	2.9 × 13	MIR	Cemented	6	Provisional prosthesis fracture
M	32	Maxillary left lateral incisor	3.25 × 10	MIR	Cemented	6	Provisional prosthesis fracture
						12	Provisional prosthesis fracture
F	43	Maxillary right lateral incisor	2.9 × 15	MIR	Cemented	6	Provisional prosthesis loosening
F	33	Maxillary left lateral incisor	3.25 × 11.5	MIR	Cemented	6	Provisional prosthesis loosening
F	67	Mandibular left canine	3.25 × 15	MIR	Cemented	6	Provisional prosthesis loosening
M	34	Mandibular right first premolar	2.9 × 15	MIR	Cemented	6	Provisional prosthesis loosening
F	44	Mandibular left central incisor	2.9 × 13	MIR	Cemented	6	Provisional prosthesis loosening
F	42	Maxillary left second molar	3.25 × 13	MIR	Cemented	6	Provisional prosthesis loosening
M	56	Maxillary right lateral incisor	3.25 × 15	STR	Cemented	12	Definitive prosthesis loosening
F	61	Maxillary right lateral incisor	2.9 × 15	STR	Cemented	12	Definitive prosthesis loosening
F	22	Maxillary left lateral incisor	3.25 × 13	STR	Cemented	12	Definitive prosthesis loosening
F	34	Maxillary left lateral incisor	2.9 × 15	STR	Cemented	12	Definitive prosthesis loosening
M	53	Mandibular left lateral incisor	3.25 × 13	STR	Cemented	6	Definitive prosthesis loosening
						18	Definitive prosthesis loosening
F	60	Mandibular left central incisor	2.9 × 10	STR	Cemented	12	Definitive prosthesis loosening
						24	Definitive prosthesis loosening
F	19	Mandibular right lateral incisor	3.25 × 15	STR	Cemented	12	Definitive prosthesis loosening

\*Between the second surgical phase and the development of the complication.

STR = single-tooth restoration; MIR = multiple-implant reconstruction supported in combination with standard-size implants.

in the mandibular left lateral incisor site of a 25-year-old woman, was lost 1 month after cementation of the temporary crown. The implant was replaced with a 15-mm-long small-diameter implant, which osseointegrated fully. Four implants (10 mm in length) that had been placed in type 4 bone in the maxilla of a 48-year-old woman were lost 3 months after the custom posts were positioned on the implant and the temporary restoration was cemented. The patient was restored with an overdenture supported by a bar splinted by 4 remaining osseointegrated standard-size implants.

One patient reported loosening of a custom post twice. The post was remade, and the problem did not recur. Nine patients reported fracture or loosening of the provisional cemented resin prostheses. These problems were solved by making appropriate adjustments to the patients' occlusion. Seven patients reported recurrent loosening of provisionally cemented definitive crowns, all of which had porcelain occlusal surfaces. This problem was solved by selective equilibration to achieve optimal occlusion and to avoid contact in lateral and protrusive movements. All prosthetic complications are summarized in Table 2.

Clinical evaluation of the peri-implant mucosa using periodontal indices revealed satisfactory results for the implant-mucosa interfaces. Dental plaque was present on only 18% of the considered surfaces, and gingival inflammation was present at 5.7%. Keratinized attached gingiva was not present at 10% of the buccal surfaces, nor at 6.4% of the lingual surfaces. A mean probing depth of 2.4 mm was recorded; this is less than the probing depths reported in some studies.<sup>2,34,35</sup> A low percentage of sites (7.0%) had bleeding on probing. The mean marginal bone loss at the last check-up, measured from the apical end of the smooth collar of the implant using intraoral radiographs, was 0.8 mm (range 0.5 to 1.2 mm) (Table 3). No differences between 2.9-mm and 3.25-mm implants or between cemented and screw-retained multiple-implant restorations were detected clinically.

## DISCUSSION

The results of the present clinical study indicated that small-diameter implants can be included in implant treatment successfully. With a projected

**Table 3 Peri-implant Marginal Bone Loss**

Time	0 to 0.5 mm n (%)	0.6 to 1.0 mm n (%)	1.0 to 1.2 mm n (%)
Baseline*	183 (100)	—	—
7 y	22 (12)	123 (67.2)	38 (20.8)

\*Prosthesis seating.

No site showed more than 1.2 mm of marginal bone loss.

success rate comparable to that obtained with standard or wide-diameter implants, they may be considered the treatment of choice in cases where space-related difficulties exist.

This 7-year retrospective study presents the results from 192 small-diameter implants for single-tooth and partial prostheses placed in 165 patients from 1992 to 1996. The implants were placed by 2 different surgeons, but all prostheses were fabricated by the same prosthodontist. The survival rate for the small-diameter implants in this study was 95.3%. The remaining 3,035 standard-size implants placed during the inclusion period in both the private practice and university settings demonstrated a 94.3% survival rate. These results are similar to those reported in other clinical studies.<sup>25,27,30</sup>

The small-diameter implant is commonly used in areas where ridge dimensions are narrow or space is limited. These conditions are frequently found in the maxilla, especially after orthodontic treatment or in situations where teeth are missing congenitally. Lack of sufficient space for a standard-size implant is also common in the mandibular incisor and maxillary premolar and canine regions. Furthermore, the placement of small-diameter implants can be an alternative to bone augmentation surgery in patients with thin posterior mandibular ridges.

The occlusal scheme was designed to avoid prematurities in eccentric movements. In maximum intercuspation, strong contacts were usually achieved in the posterior (molar and premolar) areas and minimal contacts in the anterior (canine and lateral and central incisal) areas. Once eccentric movements (lateral or protrusive) began, the anterior teeth immediately became the guidance, disoccluding the posterior teeth. All minor prosthetic problems (eg, fracture and decementation of provisional crowns, decementation of definitive crowns) were associated with occlusal prematurity.

Sixteen small-diameter implants were placed in the maxillary canine areas, and 19 small-diameter implants were placed in the mandibular canine areas

(Fig 1); all were at least 13 mm long. For canine restoration, in cases of restorations supported by a combination of small-diameter and standard-size implants, an attempt was made to concentrate the lateral guiding movements in the first premolar area. In cases of single-tooth restoration in the canine areas, canine guidance was provided. In only 3 cases did minor prosthetic problems occur with implants placed in the canine areas (Table 2). The problems were solved with minor occlusal adjustment by avoidance of occlusal overload on those implants. In 1 patient, a 2.9-mm-wide implant was positioned in the mandibular right first molar site, where a thin crestal ridge did not allow placement of a wider-diameter implant. The definitive restoration in that situation involved a ceramometal crown with a porcelain occlusal surface. The crown shape was reduced to the dimensions of a mandibular premolar to better control the occlusal contacts of the prosthesis. One patient reported the loosening of a custom post on a 2.9-mm-wide mini-implant. The post showed some casting imperfections at the hexagon level. After it was remade, the problem did not recur.

Comparable results were achieved for mandibular and maxillary small-diameter implants. Optimal primary stability was sought in all surgical procedures, especially in those in soft bone. No differences between the 2.9-mm and 3.25-mm implants, between small-diameter implants used for single-unit restorations and those included in multiple-implant restorations, or between cemented and screw-retained multiple-implant restorations were detected clinically. However, the study did not include any partial prostheses supported solely by small-diameter implants, and the impact of standard implants on the success of the prostheses supported by both small-diameter and standard implants could not be evaluated clearly. Therefore, this investigation does not support the use of small-diameter implants alone to support multiunit prostheses.

## CONCLUSIONS

One hundred sixty-five patients received 192 small-diameter implants between 1992 and 1996. The overall survival rate was 95.3%; the failures were related to poor bone quality at the recipient site and to occlusal problems. Within the limitations of this investigation, it can be concluded that small-diameter restorations can be a valid alternative in many clinical situations where space or bone availability does not permit the use of standard or wide-diameter implants.

## ACKNOWLEDGMENTS

The investigators express their special thanks to the Centro di Odontoiatria Riabilitativa (COR) for its generous support.

## REFERENCES

- Lazzara RJ. Criteria for implant selection: Surgical and prosthetic considerations. *Pract Periodontics Aesthet Dent* 1994; 6:55-62.
- Cordioli G, Castagna S, Consolati E. Single-tooth implant rehabilitation: A retrospective study of 67 implants. *Int J Prosthodont* 1994;7:525-531.
- Albrektsson T, Zarb G, Worthington P, Eriksson RA. The long-term efficacy of currently used dental implants: A review and proposed criteria of success. *Int J Oral Maxillofac Implants* 1986;1:11-25.
- Brånemark P-I, Hansson BO, Adell R, et al. Osseointegrated implants in the treatment of the edentulous jaw. Experience from a 10-year period. *Scand J Plast Reconstr Surg Suppl* 1977;16:1-132.
- Adell R, Eriksson B, Lekholm U, Brånemark P-I, Jemt T. Long-term follow-up study of osseointegrated implants in the treatment of totally edentulous jaws. *Int J Oral Maxillofac Implants* 1990;5:347-359.
- Ahlqvist J, Borg K, Gunne J, Nilson H, Olsson M, Astrand P. Osseointegrated implants in edentulous jaws: A 2-year longitudinal study. *Int J Oral Maxillofac Implants* 1990;5: 155-163.
- Zarb GA, Schmitt A. Osseointegration and the edentulous predicament. The 10-year-old Toronto study. *Br Dent J* 1991;170:439-444.
- Adell R, Lekholm U, Rockler B, Brånemark P-I. A 15-year study of osseointegrated implants in the treatment of the edentulous jaw. *Int J Oral Surg* 1981;10:387-416.
- Jemt T. Fixed implant-supported prostheses in the edentulous maxilla. A five-year follow-up report. *Clin Oral Implants Res* 1994;5:142-147.
- van Steenberghe D. A retrospective multicenter evaluation of the survival rate of osseointegrated fixtures supporting fixed partial prostheses in the treatment of partial edentulism. *J Prosthet Dent* 1989;61:217-223.
- Zarb GA, Schmitt A. The longitudinal clinical effectiveness of osseointegrated dental implants in posterior partially edentulous patients. *Int J Prosthodont* 1993;6:189-196.
- Zarb GA, Schmitt A. The longitudinal clinical effectiveness of osseointegrated dental implants in anterior partially edentulous patients. *Int J Prosthodont* 1993;6:180-188.
- Jemt T, Lekholm U, Adell R. Osseointegrated implants in the treatment of partially edentulous patients: A preliminary study on 876 consecutively placed fixtures. *Int J Oral Maxillofac Implants* 1989;4:211-217.
- Jemt T, Lekholm U, Grondahl K. A 3-year follow-up study of early single implant restorations ad modum Brånemark. *Int J Periodontics Restorative Dent* 1990;10:340-349.
- Schmitt A, Zarb GA. The longitudinal clinical effectiveness of osseointegrated dental implants for single-tooth replacement. *Int J Prosthodont* 1993;6:197-202.
- Ekkfeldt A, Carlsson GE, Börjesson G. Clinical evaluation of single-tooth restorations supported by osseointegrated implants: A retrospective study. *Int J Oral Maxillofac Implants* 1994;9:179-183.
- Haas R, Mensdorff-Pouilly N, Mailath G, Watzek G. Brånemark single tooth implants: A preliminary report of 76 implants. *J Prosthet Dent* 1995;73:274-279.
- Engquist B, Nilson H, Astrand P. Single-tooth replacement by osseointegrated Brånemark implants. A retrospective study of 82 implants. *Clin Oral Implants Res* 1995;6:238-245.
- Avivi-Arber L, Zarb GA. Clinical effectiveness of implant-supported single-tooth replacement: The Toronto study. *Int J Oral Maxillofac Implants* 1996;11:311-321.
- McMillan AS, Allen PF, Bin Ismail I. A retrospective multicenter evaluation of single tooth implant experience at three centers in the United Kingdom. *J Prosthet Dent* 1998;79: 410-414.
- Ivanoff CJ, Sennerby L, Johansson C, Rangert B, Lekholm U. Influence of implant diameters on the integration of screw implants. An experimental study in rabbits. *Int J Oral Maxillofac Surg* 1997;26:141-148.
- Block MS, Delgado A, Fontenot MG. The effect of diameter and length of hydroxylapatite-coated dental implants on ultimate pullout force in dog alveolar bone. *J Oral Maxillofac Surg* 1990;48:174-178.
- Kido H, Schulz EE, Kumar A, Lozada J, Saha S. Implant diameter and bone density: Effect on initial stability and pull-out resistance. *J Oral Implantol* 1997;23:163-169.
- Davarpanah M, Martinez H, Tecucianu JE, Celletti R, Lazzara R. Small-diameter implants: Indications and contraindications. *J Esthet Dent* 2000;12:186-194.
- Polizzi G, Fabbro S, Furri M, Herrmann I, Squarzoni S. Clinical application of narrow Brånemark System implants for single-tooth restorations. *Int J Oral Maxillofac Implants* 1999;14:496-503.
- Vigolo P, Givani A. Clinical evaluation of single-tooth mini-implant restorations: A five-year retrospective study. *J Prosthet Dent* 2000; 84:50-54.
- Andersen E, Saxegaard E, Knutsen BM, Haanaes HR. A prospective clinical study evaluating the safety and effectiveness of narrow-diameter threaded implants in the anterior region of the maxilla. *Int J Oral Maxillofac Implants* 2001;16:217-224.
- Wehrbein H, Merz BR, Diedrich P. Palatal bone support for orthodontic implant anchorage—A clinical and radiological study. *Eur J Orthod* 1999;21:65-70.
- Gedrange T, Bourauel C, Kobel C, Harzer W. Three-dimensional analysis of endosseous palatal implants and bones after vertical, horizontal, and diagonal force application. *Eur J Orthod* 2003;25:109-115.
- Hallman M. A prospective study of treatment of severely resorbed maxillae with narrow nonsubmerged implants: Results after 1 year of loading. *Int J Oral Maxillofac Implants* 2001;16:731-736.
- Zinsli B, Säggerer T, Mericske E, Mericske-Stern R. Clinical evaluation of small-diameter ITI implants: A prospective study. *Int J Oral Maxillofac Implants* 2004;19:92-99.
- Lekholm U, Zarb GA. Patient selection and preparation. In: Brånemark P-I, Zarb GA, Albrektsson T (eds). *Tissue-Integrated Prostheses: Osseointegration in Clinical Dentistry*. Chicago: Quintessence, 1985:199-209.
- Cox JF, Pharoah M. An alternative holder for radiographic evaluation of tissue-integrated prostheses. *J Prosthet Dent* 1986;56:338-341.
- Lekholm U, Adell R, Lindhe J, et al. Marginal tissue reaction at osseointegrated titanium implants. II. A cross-sectional retrospective study. *Int J Oral Surg* 1986;15:53-61.
- Apse P, Zarb GA, Schmitt A, Lewis DW. The longitudinal effectiveness of osseointegrated dental implants. The Toronto study: Peri-implant mucosal response. *Int J Periodontics Restorative Dent* 1991;11:94-111.