DENTISTRY TODAY

Aesthetics
Clinical Update
CE Articles
Dental Materials
Dental Medicine
Diagnosis
Digital Impression Technology
Endodontics
Ergonomics
Focus On

Forensic Dentistry
Geriatric Dentistry
Hygiene
Implants
Impressions
Infection Control
Interdisciplinary Dentistry
Interview
Laboratory
Management
Materials
Microdentistry
New Directions
Practice Management
Restorative
Oral Cancer Screening
Occlusion

- Oral Medicine
- Oral-Systemic connection
- Orthodontics
- Pediatric Dentistry
- Periodontics
- Pharmacology
- Pain Management
- Prevention
- Prosthodontics
- Psychology
- Radiography
- Post-and-Core Technique
- Regulatory
- Restorative
- Sleep Disorders
- Sports Dentistry
- Technology

Achieving Success With Small-Diameter Implants

Category: Prosthodontics Created: Thursday, 08 January 2015 20:16 Written by Paresh B. Patel, DDS

Print Email

INTRODUCTION

It is without question that dental implants are one of the most successful additions to modern dentistry. With a success rate of greater than 95%, the root form implant should be considered to restore any edentulous area. However, when we are presented with the need to manage a highly resorbed ridge, significant issues for the surgeon and restorative team arise if only the use of a standard body implant (3.7 mm or larger) is considered. These issues can be anatomical, medical, financial, or restorative.

Anatomical challenges are closely associated with how much residual alveolar ridge remains (quantity) and also its density (quality). These can sometimes be overcome with additional surgical procedures such as ridge expansion, block grafting, and other hard- and soft-tissue procedures. If these solutions are not accepted, the use of a much less invasive procedure should be considered, such as the small-diameter implant (SDI) (also referred to as the mini implant).

SDIs have been around in their FDA-approved form since 1997 and share similar surface texture, coatings, and titanium grade to their larger counterparts. Most implant manufacturers now have added SDIs to their system. These SDIs now are available in one- and 2-piece versions as well as crown and bridge prosthetic options.

Medical challenges should be addressed by utilizing the most minimally invasive surgical plan. The incorporation of 3-D cone beam (CB) technology is rapidly increasing and can allow for presurgical planning to avoid mandatory grafting. A CBCT surgical guide can be created to deliver the implant into the bone with a flapless technique reducing surgical trauma. This may be a prudent solution for patients with systemic conditions who are unable to tolerate lengthy healing times. It is important to note that a CBCT-based surgical guide is much different that a prosthetic guide that is based on a pan x-ray and a stone model.

Restorative challenges are usually the management of restricted restorative space in the mesial-distal or buccal-lingual direction. This has always posed a high-risk problem in the aesthetic area. Too wide of an implant will create potential for bone and/or soft-tissue loss. Convergent roots can also preclude the use of a standard body implant. In these cases, an SDI may allow for the placement of the implant and still allow proper bone support, soft-tissue space, and proper spacing from adjacent tooth roots.

SDIs can be used to retain maxillary or mandibular dentures. Due to reduced surface area, it is recommended to utilize 4 SDIs in the mandible and 6 SDIs in the maxilla. The residual ridge should be of Misch Type I or II to ensure a successful case. If the SDI selected is of a one-piece design, then immediate loading must be addressed. Primary stability should be at a minimum of 30 Ncm on all the implants and a stable tissue supported denture should be delivered. The implants should also be placed as parallel as possible to minimize off-axis loads.

CASE REPORTS

Case 1: Multiple Unit Fixed Restorations

Diagnosis and Treatment Planning—A 54-year-old female presented in general good health with a history of diabetes. She had progressively lost her teeth during the past 15 years, with the last of them being extracted about 5 years ago. She was unhappy with her existing dentures due to poor retention and difficulty with eating. Both ridges were examined and found to be moderately atrophic (Figures 1 and 2). A CBCT scan was taken (iCAT FLX) with the dual-scan protocol to facilitate a prosthetically driven treatment plan (Figures 3 and 4).

Figure 1. (*Case 1*) Pre-op

Figure 2. Pre-op

maxillary ridge.

mandibular ridge.

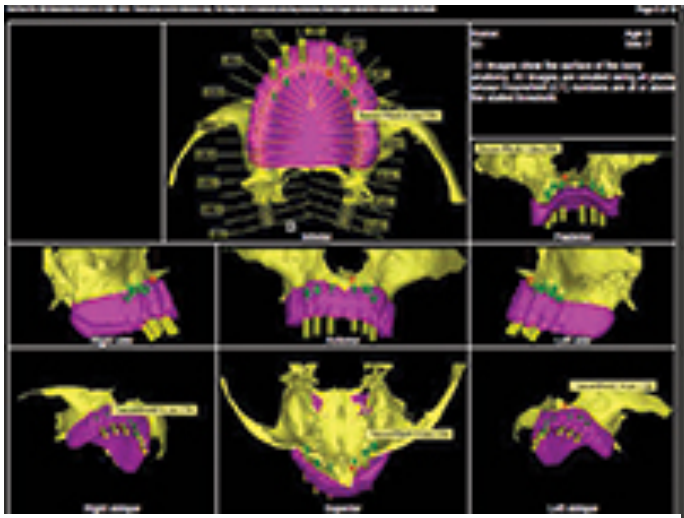

Figure 3. iCAT FLX Tx PL (maxilla).

Figure 4. iCAT FLX Tx PL (mandibular).

Figure 5. Mandibular surgical guide.

Figure 6. Maxillary surgical guide.

Figure 7. Maxillary

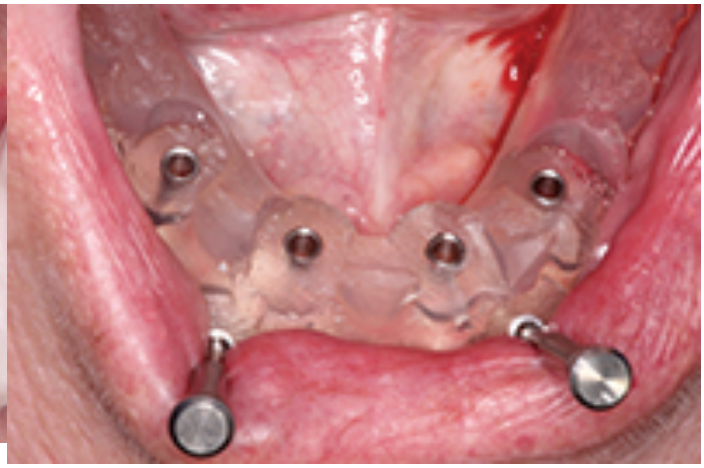

Figure 8. Mandibular

surgical guide seated.

Figure 9. Implant motor and pilot drill.

surgical guide seated.

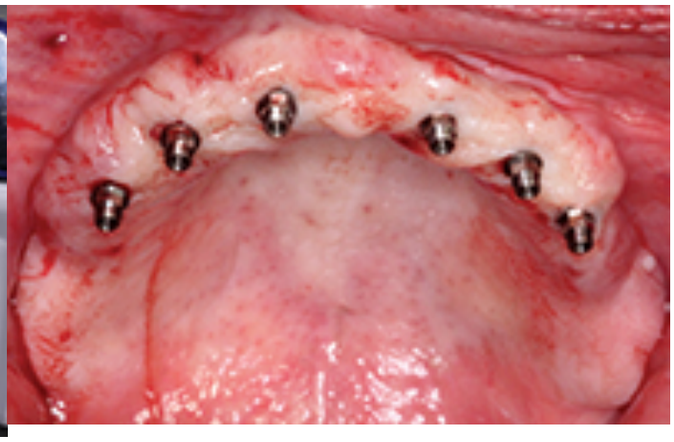

Figure 10. LOCATOR Overdenture Implant (LODI) System (ZEST Anchors) fully seated.

Figure 11. The LOCATOR attachment (ZEST Anchors) was secured on the upper arch.

Figure 12. LOCATOR attachments on the lower arch.

Figure 13. FitTest (Quick Up System [VOCO

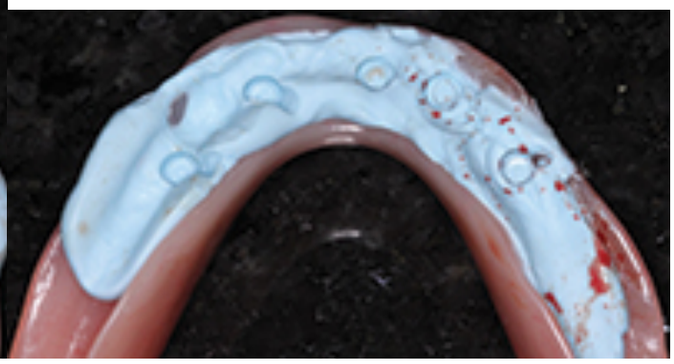

Figure 14. FitTest was allowed to set and show

America] materials were placed.

the relief areas to be created.

Figure 15. Relief wells in maxillary prosthesis.

Figure 16. Relief wells in mandibular prosthesis.

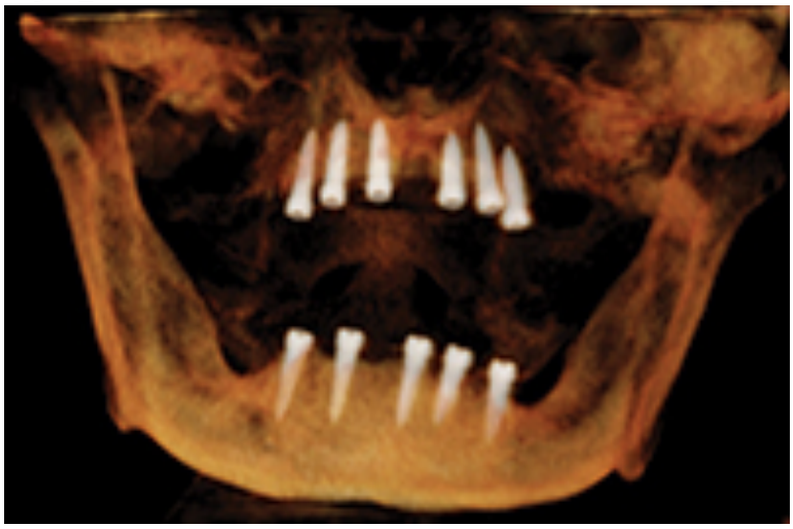

Figure 17. iCAT FLX post scan.

Due to the height and width of the remaining bone, 6 SDIs would be placed in the maxilla and 4 SDIs in the mandible to support overdentures. The SDIs selected for this case were of a 2-piece design with a LOCATOR attachment (LOCATOR Overdenture Implant System [LODI] [ZEST Anchors]). The low profile of the attachment would allow for a less obtrusive denture and a variety of retentive inserts. After the treatment plan was approved by the patient, surgical guides

(Anatomage) were ordered (Figures 5 and 6).

Clinical Protocol—On the day of surgery, the surgical guides were tried in to verify stability and fit (Figures 7 and 8). A single 1.6-mm pilot bit was used to create the osteotomies through the surgical guide in the maxilla using an implant motor (Aseptico AEU7000) with copious irrigation (Figure 9). The pilot guide was removed and the LODIs were inserted and carried to depth (Figure 10). All 6 SDIs were confirmed to have at least 30 Ncm of torque, and the LOCATOR attachment was secured (Figure 11). This protocol was duplicated on the lower arch (Figure 12). To ensure that the existing dentures would fit passively over the SDIs, FitTest (Quick Up System [VOCO America]) material was placed and allowed to set, showing where relief areas would need to be created (Figures 13 and 14). Once the relief was complete, the process was repeated until a verified passive denture could be obtained (Figures 15 and 16). The dentures could then be soft relined (Ufi Gel [VOCO America]). A final CBCT scan was taken (iCAT FLX) to ensure that all the SDIs were fully encased in bone and no vital anatomical structures were violated (Figure 17).

Case 2: Single-Unit Fixed Prosthetics

SDIs can be an excellent solution to support a single crown in areas of reduced interdental space (less than 5 mm between adjacent teeth) where it would be impossible to place a larger implant. These areas could be maxillary lateral and mandibular incisors. Case selection should have a bone type of Misch I or II and off-axis occlusal forces should be minimized by designing the single-unit crown to have implant-protected occlusion. The use of a single SDI to support a crown much larger than a maxillary lateral is still quite controversial.

Figure 18. (Case 2.) Pre-op photo showing missing lateral.

Figure 19. Digital periapical (PA) (DEXIS) for mesiodistal width.

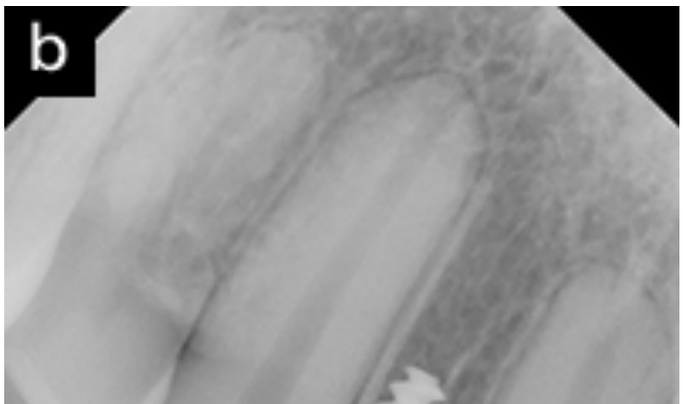

Figure 20a. A 1.8-mm pilot bit.

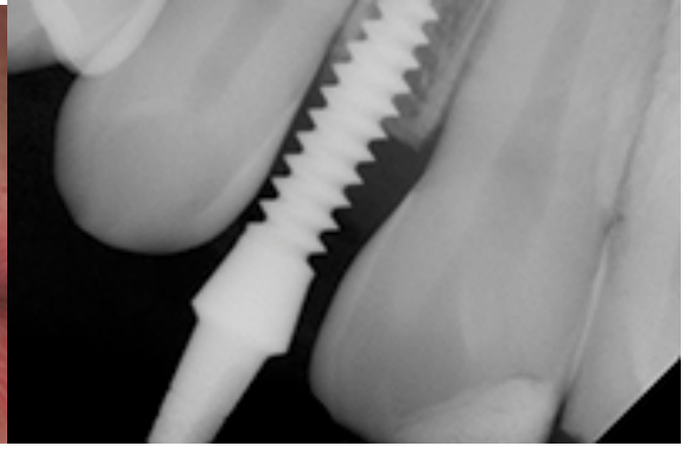

Figure 20b. Digital PA at initial placement.

Figure 21. Initial placement.

Figure 22. Komet titanium abutment bur.

Diagnosis and Treatment Planning—An 18-year-old young adult presented to our office after completion of orthodontics several months prior. He had lost his retainer/flipper that also replaced his missing upper lateral No. 7 (Figure 18). A digital radiograph (Platinum [DEXIS]) was taken to see the position of adjacent roots, and it confirmed an extremely narrow mesio-distal space (Figure 19). It was decided to utilize a one-piece, 3.0-mm diameter crown and bridge SDI (i-

Mini [OCO Biomedical]). The decision to use this brand was due to the i-Mini's aggressive thread design that allows for compression and fixation of the implant in Type II bone.

Clinical Protocol—A 1.8-mm pilot bit in the Aseptico handpiece was used to carefully create the initial osteotomy (Figure 20a) and another digital radiograph was taken to confirm a parallel path between the adjacent roots (Figure 20b). A final 2.4-mm osseoformer was used to prepare the bone, and the one-piece SDI was inserted (Figure 21). After final depth was reached, the prosthetic head of the implant was shaped for interarch space with a high-speed handpiece (KaVo) and a titanium abutment prep bur (Komet) (Figure 22). A conventional vinyl polysiloxane (VPS) impression (Take 1 Advanced [Kerr]) was taken using light- and heavy-body materials. The case was then sent to our dental laboratory team for the fabrication of a monolithic zirconia crown (BruxZir [Glidewell Laboratories]) (Figure 23).

Case 3: Multiple Unit Fixed Restorations

Many of the same principles of utilizing an SDI for single-unit fixed restorations should be embodied when applying their use for multiple-unit fixed restorations. All fixed units should be splinted together to help dissipate force and minimize any micromovement. In function, the occlusal loads can be distributed over the multiple splinted SDIs. This reduces the functional load on any one SDI and increases the bone-to-implant contact. For full-arch cases, it is prudent to increase the number of SDIs in order to reach the desired surface area to prevent implant overload.

Diagnosis and Treatment Planning—A 62-year-old female presented with the chief complaint of difficulty chewing and keeping her dentures in place. The patient stated she had been wearing the full upper and lower dentures for 15 years. The clinical exam revealed a healthy appearance to the edentulous tissue (Figure 24). The patient stated that her experience with dentures had made her unhappy and self-conscious with her overall appearance; so much so that she wanted to have “fixed teeth.” A medical history review revealed the patient had had a previous heart attack and continued the use of Plavix, an anticoagulant medication. The patient was also diabetic, controlled with medication.

To minimize surgical trauma and to increase the efficiency of implant-guided surgery, a flapless technique was to be employed for implant placement. A CBCT scan (iCAT FLX) was taken for treatment planning and fabrication of a surgical guide. Upon completion of the CT scan, it was evident that the residual ridges were highly resorbed and would require the use of SDIs or additional surgical procedures to accommodate standard body implants. To keep within our concept of minimally invasive dentistry, multiple SDIs were prescribed to support the full-arch restorations.

The treatment plan options were discussed with the patient and the final decision was made and approved by the patient. CBCT surgical guides (Materialise) were made for upper and lower full-arch implant placement.

Figure 23. Monolithic zirconia restoration (BruxZir [Glidewell Laboratories]).

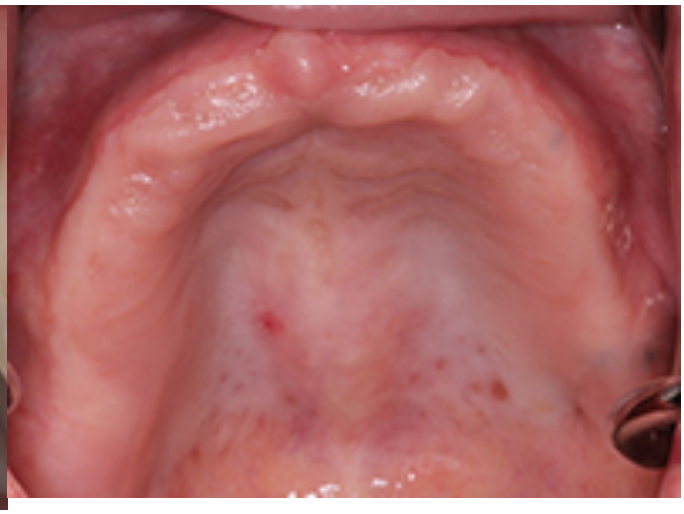

Figure 24. (Case 3). Pre-op maxillary ridge.

Figure 25. Maxillary surgical guide.

Figure 26. Mandibular surgical guide.

Figure 27. Initial osteotomy.

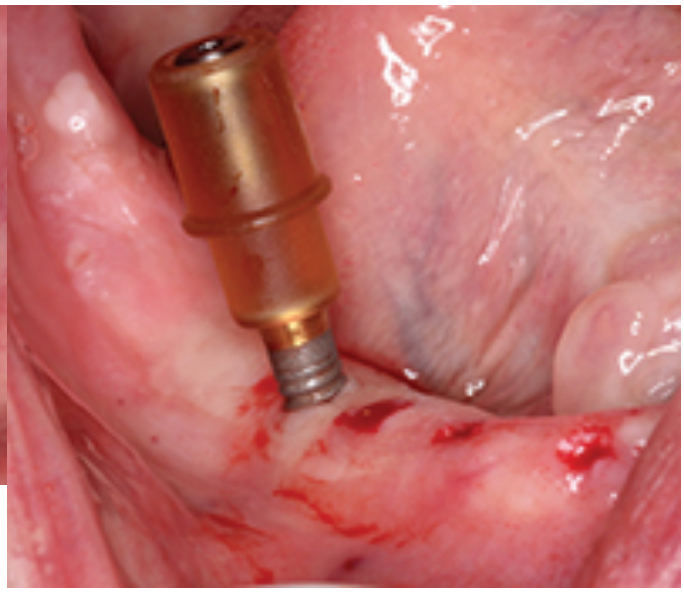

Figure 28. Hand insertion of an OCO Biomedical implant.

Figure 29. OCO Biomedical SDIs (lower

Figure 30. OCO Biomedical SDIs (upper

arch) fully inserted.

Figure 31. Final iCAT FLX scan.

arch) fully inserted.

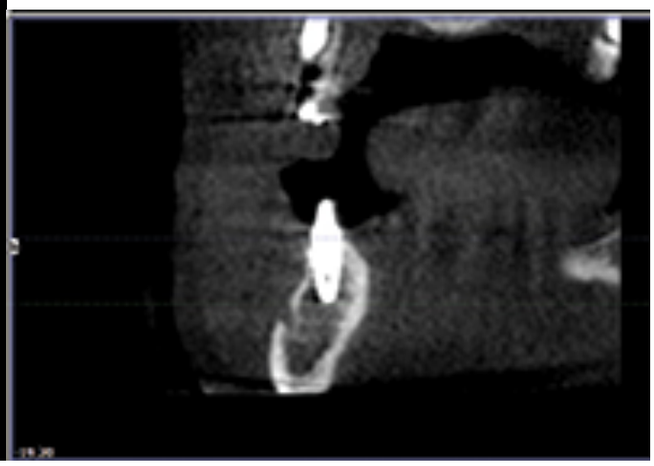

Figure 32. iCAT slice.

Figure 33. Final full-arch prosthesis.

Figure 34. Final full-arch upper and lower prostheses.

Clinical Protocol—The patient presented on her appointed day with no changes made to her daily medication regimen. Infiltration with local anesthetic was administered. The surgical guides were tried in to ensure proper fit and stability (Figures 25 and 26). The surgical guides were retained, and a 1.8-mm pilot drill was used in each site to full length. The guides were then removed, and an immediate photograph was taken to illustrate the minimal amount of trauma

to the implant surgical sites (Figure 27). Each SDI (3.25-mm ERI [OCO Biomedical]) was started by hand to one half depth (Figure 28), and then taken to full depth using the Aseptico surgical motor. With the exception of the posterior upper right site, all sites accepted a 2-piece 3.25 x 12 mm in the maxilla and 3.25 x 10 mm in the mandible (Figures 29 and 30). A post-implant placement CT scan (iCAT FLX) was taken; it demonstrated parallel placement in the panoramic view very closely resembling what was treatment planned (Figure 31). In addition, the 3-D slice view showed that the implants were fully encased in bone, away from the nerve canal and engaging the cortical plate for maximum stability (Figure 32). Solid abutments (OCO Biomedical) were placed and torqued to 30 Ncm. Full-arch impressions of the duplicated dentures were taken with a VPS material (Take 1 Advanced). The impressions were then delivered to the lab team and full-arch fixed bridges were fabricated for final cementation (Figures 33 and 34).

CLOSING COMMENTS

With the use of guided surgery and SDIs, more patients can undergo implant surgery to achieve their desired goals to have teeth. SDIs, along with minimally invasive dentistry, are an ideal treatment solution to consider when standard-body implants are not feasible without additional procedures.

Dr. Patel is a graduate of University of North Carolina at Chapel Hill School of Dentistry and the Medical College of Georgia/American Academy of Implant Dentistry Maxi Course. He is the co-founder of the American Academy of Small Diameter Implants and is a clinical instructor at the Reconstructive Dentistry Institute. He has placed more than 2,500 mini implants and has worked as a lecturer and clinical consultant on mini implants for various companies. He can be reached at pareshpateldds2@gmail.com or via the Web site dentalminiimplant.com.

Disclosure: Dr. Patel reports no disclosures.

Prev

Next

DENTISTRY TODAY

Dentistry Today is The Nation's Leading Clinical News Magazine for Dentists. Here you can get the latest dental news from the whole world quickly.

E-mail Subscribe

Popular Item

The World’s Top Dental Schools: 201...

10 March 2017

The US Dominates the ARWU’s Best De...

26 July 2018

World’s Best Dental Schools Ranked

03 March 2016

Recent News

Hygienists Encouraged to Have the C...

10 January 2019

3-D Printing Improves Care at Unive...

10 January 2019

Include Google Ads in Your 2019 Mar...

10 January 2019

Product Highlights



3-D Scanner App Aids in Smile Desig...

10 January 2019



Universal Adhesive Doesn't Require...

09 January 2019



Post-Treatment System Prevents Peri...

08 January 2019

Copyright © 2019 Dentistry Today. All Rights Reserved.