






GET A \$50 AMAZON CARD when you take a demo of Lighthouse 360  

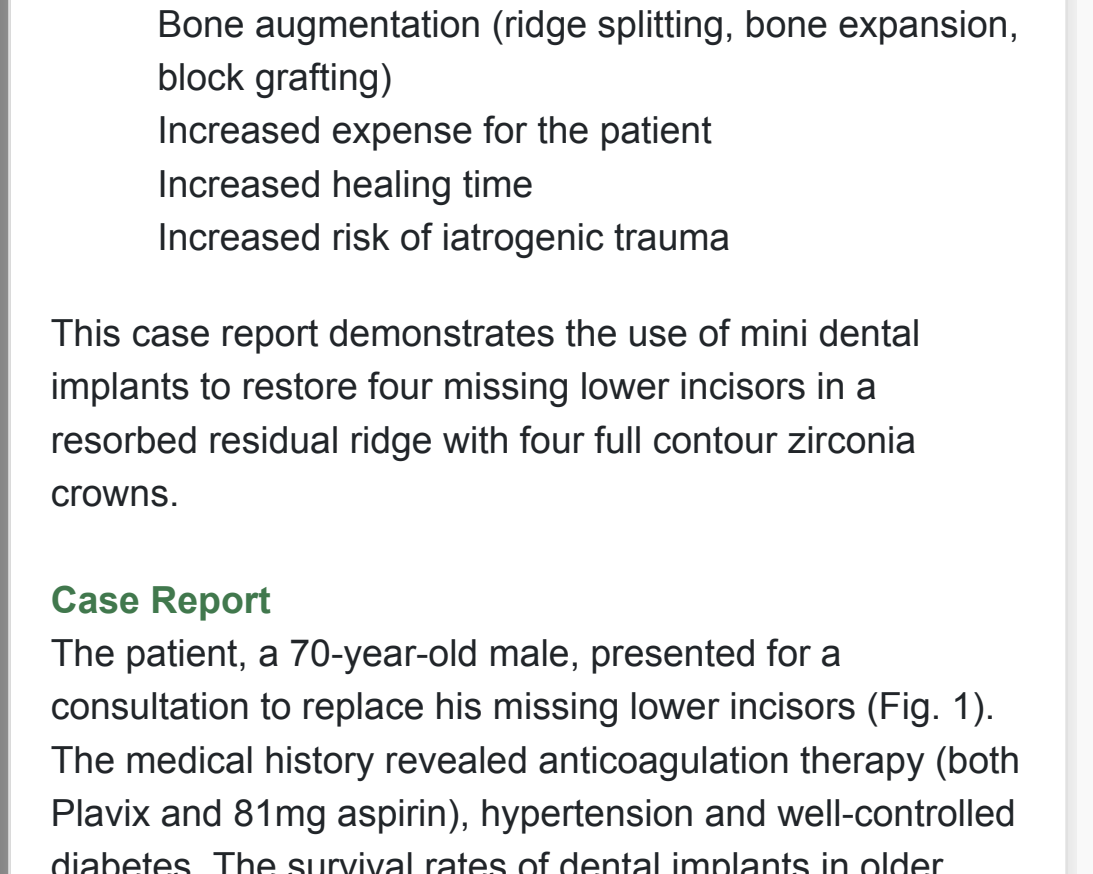
Immediate Load Mini Dental Implant-Supported Zirconia Crowns by Paresh B. Patel, DDS and Andrea Mascolo, DDS

[Home](#) > [DentalTown Magazine](#) > [February 2012](#) > [Article](#)

[add comment](#)

[More Options](#) v

 Share 0  Tweet  Share  Save 0  Share



Introduction

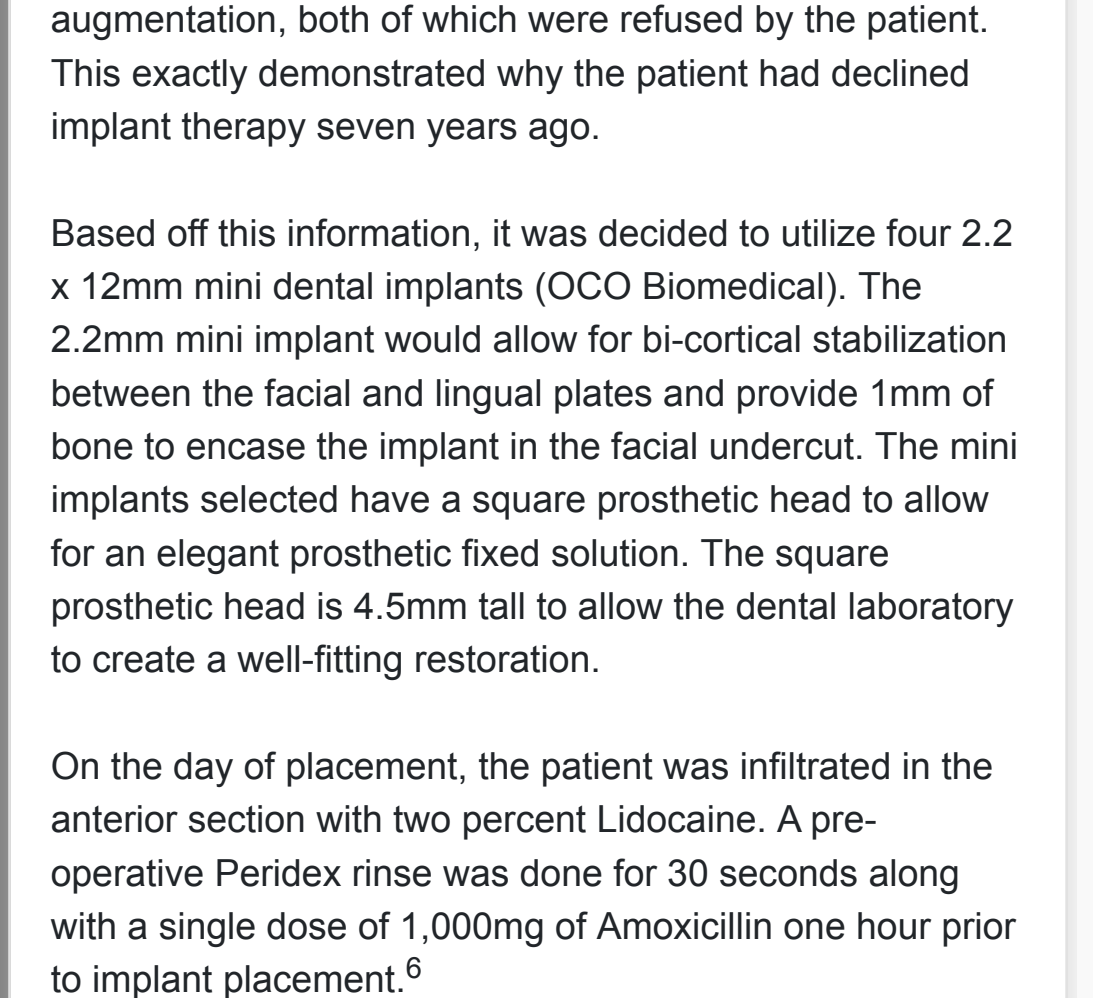
As implant dentistry becomes more popular, one-piece mini dental implants are increasing in use. There have been several studies that demonstrate that mini dental implants can provide adequate stability for fixed restorations.¹ Although considered by some as taboo in mainstream dentistry, the literature reports success rates similar to that of conventional implant therapy.² The purpose of this case report is to challenge traditional thinking and offer patients choices in appropriate situations. All too often patients present to our practices with an inadequate volume of bone for standard size implants (3.75mm). Dr. Gordon Christensen's proposed guidelines indicate the need for 6mm of bone in the facial-lingual orientation to accommodate a standard size root form implant.³ To correct these deficiencies and arrive at 6mm of width, additional surgical procedures might be necessary. Some of these patients, who decline additional surgery, would move forward with implant therapy if presented with a viable alternative: the mini dental implant. This kind of alternative would remove the roadblocks of:

- Bone augmentation (ridge splitting, bone expansion, block grafting)
- Increased expense for the patient
- Increased healing time
- Increased risk of iatrogenic trauma

This case report demonstrates the use of mini dental implants to restore four missing lower incisors in a resorbed residual ridge with four full contour zirconia crowns.

Case Report

The patient, a 70-year-old male, presented for a consultation to replace his missing lower incisors (Fig. 1). The medical history revealed anticoagulation therapy (both Plavix and 81mg aspirin), hypertension and well-controlled diabetes. The survival rates of dental implants in older patients can be affected by certain systemic conditions associated with aging.⁴ Patients who undergo implant therapy face medical and surgical risks that are similar to those of outpatient oral surgical procedures, regardless of age. The dentist should evaluate the patient for systemic conditions that might compromise healing and the systemic effects of medications.



The lower incisors were lost over a period of time 20 to 25 years ago. His current prosthesis was a cast metal partial that he only wore in social situations. In fact, he called it his "church partial" due to the fact he only wore it when sitting in church with his wife. His desire was to replace the missing incisors with a fixed prosthesis to increase his quality of life, both from a functional and aesthetic perspective. A pan X-ray and study casts were taken for analysis. The lower edentulous area was mapped using the bone-sounding technique as described by Flanagan.⁵ A severe facial undercut was noted midway down the crest along the entire ridge. A standard size implant would not fit without either reducing the ridge or some bone augmentation, both of which were refused by the patient. This exactly demonstrated why the patient had declined implant therapy seven years ago.

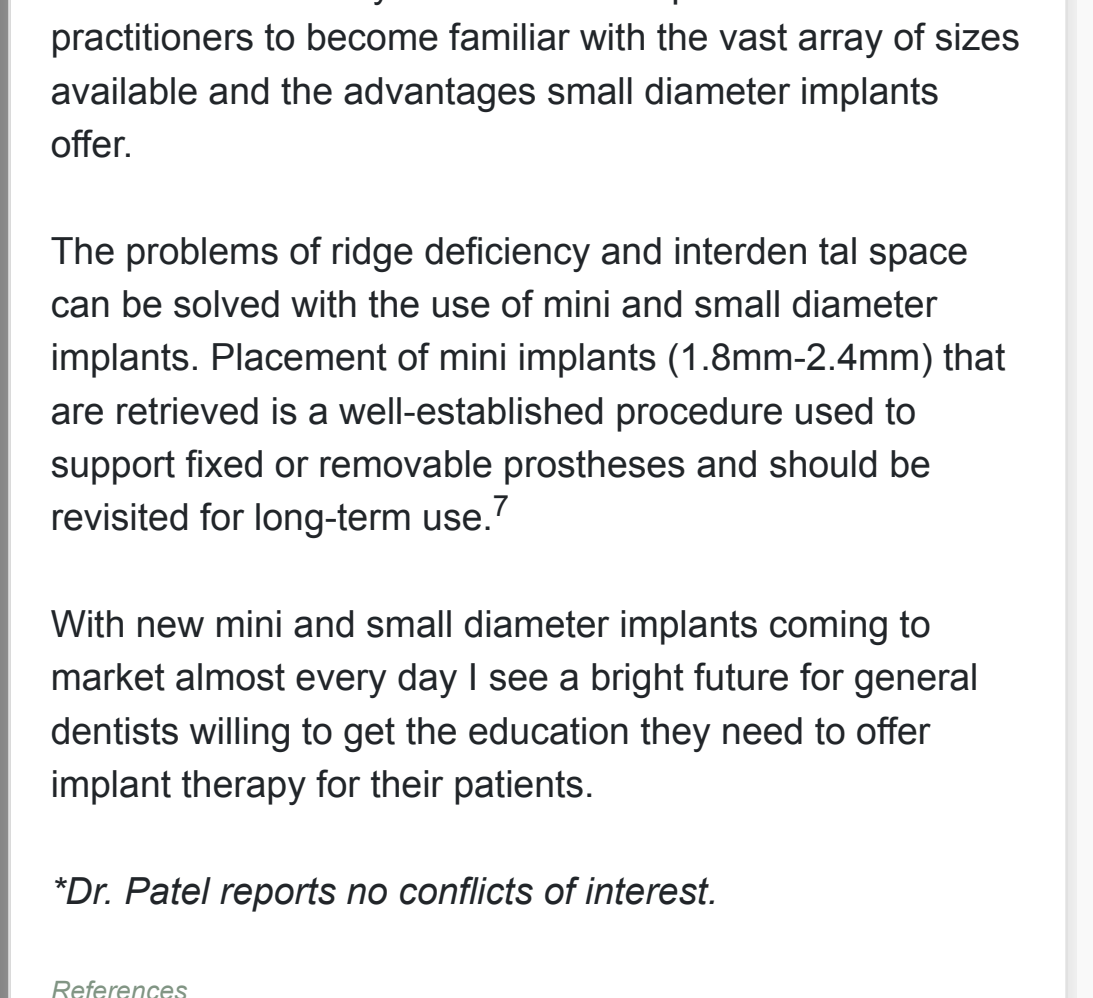
Based off this information, it was decided to utilize four 2.2 x 12mm mini dental implants (OCO Biomedical). The 2.2mm mini implant would allow for bi-cortical stabilization between the facial and lingual plates and provide 1mm of bone to encase the implant in the facial undercut. The mini implants selected have a square prosthetic head to allow for an elegant prosthetic fixed solution. The square prosthetic head is 4.5mm tall to allow the dental laboratory to create a well-fitting restoration.

On the day of placement, the patient was infiltrated in the anterior section with two percent Lidocaine. A pre-operative Peridex rinse was done for 30 seconds along with a single dose of 1,000mg of Amoxicillin one hour prior to implant placement.⁶

The four sites were marked with a #8 surgical length round bur (Komet) (Fig. 2). A 1.5mm pilot bit from the OCO Mini Implant Kit was used in the externally irrigated implant handpiece (Aseptic) with a drill stop set short of the implant length (Fig. 3). An interesting feature of mini implants is that due to their smaller diameter, the surgical process is greatly simplified. Only one pilot bit is used to take advantage of the self-tapping, bone-condensing design of the mini implant and the visco-elastic property of alveolar bone. The removal of live bone to the diameter of the implant with multiple drills is not necessary. In fact, in most cases with bone mapping, the mini implant can be placed flaplessly, thus preserving the blood supply from the periostium and gingival tissue. This greatly reduces the potential of bone die back as might be expected when making a full flap incision for conventional size implants.

The mini implant is removed from its sterile vile and can be placed by hand with the ulturn cap and ratchet wrench or with an implant handpiece driver (Fig. 4). I prefer to place the mini implant with a handpiece for several reasons. First, the implant motor can be set to 10RPM and 40NCM of torque, thus reducing the potential of overheating the bone from friction or speed of placement. Second, the use of the implant handpiece prevents lateral torque and creates a true vertical force vector. This ensures a nice tight cortical collar of bone around the mini implant with great primary stability and less potential for micro-movement after surgery. The strong mechanical stability creates osseofixation during the primary phase of bone healing and helps promote osseointegration during the secondary phase over the next eight to 12 weeks. Once all four OCO mini implants were placed to full length, a standard crown and bridge impression was taken with light and heavy body PVS (Capture PVS Glidewell Direct) with the use of the OCO impression snap caps (Figs. 5&6). In this case it was decided to demonstrate the use of an iTero digital impression scanner (Cadent). The mini implants and upper and lower jaws were scanned headside in the mouth and a virtual model was created (Fig. 7). From this virtual model four individual BruxZir full contour zirconia crowns were fabricated by Glidewell Dental Lab. A resin model was ordered to confirm the fit and contacts (Figs. 8,9a&9b). As more manufacturers are entering the digital impression arena a scan from an IOS FastScan (IOS Technologies) or CEREC (Sirona) could have been used and uploaded via CEREC Connect to create the BruxZir crowns.

I would have rather splinted the four crowns together but it was the patient's desire to have four individual crowns and the risks associated with not splinting them together were presented at the original appointment.



The patient's existing partial denture was relieved with a cylinder-shaped acrylic bur (Komet) to fit over the mini implants. At the patient's seat appointment two weeks later the tissue had already started to climb up the mini dental implants (Fig. 9c). This was a perfect opportunity to utilize a soft-tissue diode laser (AMD Picasso Lite) to remove the overgrowth prior to cementing the crowns. The use of a diode laser allows the clinician to only ablate the target tissue and dramatically minimizes the inflammatory response and bleeding, not to mention that you can touch the implant without fear of disrupting the osseointegration process. PFG gel (Steven's Pharmacy) was used to anesthetize the tissue for a one-shot appointment. Once the tissue had been recontoured, the aesthetics, fit and occlusion of the zirconia crowns were evaluated. After patient approval, the crowns were cemented with Maxcem Elite resin cement (Kerr Dental) (Figs. 10a&10b). The patient has successfully functioned with the fixed crowns with no complications for one year (Fig. 11).

Discussion

In this case example, the reduced facial-lingual dimension presented a problem for traditional implant therapy. The available bone topography also presented a surgical challenge. With creative but effective treatment planning, a viable solution was presented to attain our patient's desires. The incorporation of new dental technologies (digital impressions, CAD-milled zirconia restorations and soft-tissue diode lasers) all help to create final products that just a few years ago would have been impossible to offer.

The mini implant can offer advantages in certain situations such as:

- Multiple mini implants can offer adequate surface area needed for successful fixed prosthetics
- Engagement of the cortical plates in thin ridges for excellent primary stabilization.
- One-piece design offers similar strength in a smaller diameter (no screw hole)
- No micro-gap – only radicular and coronal areas in a one-piece design
- Flapless approach to maximize the available blood supply and reduce healing time
- Less volume of bone is removed thus leaving more native tissue to disperse forces
- A pre-contoured abutment that can be shaped in vivo if needed

Conclusion

In a perfect ivory tower practice where time and money are not an issue it would be desirable to replace the missing tissues (hard and soft) to ideal conditions prior to implant therapy. However for most patients, this kind of implant therapy is still unattainable. When possible, patients should be offered traditional implant therapy. With the inclusion of mini dental implants as an alternative, many additional patients can be given a choice other than go home with what they have. It is now up to individual practitioners to become familiar with the vast array of sizes available and the advantages small diameter implants offer.

The problems of ridge deficiency and interdental space can be solved with the use of mini and small diameter implants. Placement of mini implants (1.8mm-2.4mm) that are retrieved is a well-established procedure used to support fixed or removable prostheses and should be revisited for long-term use.⁷

With new mini and small diameter implants coming to market almost every day I see a bright future for general dentists willing to get the education they need to offer implant therapy for their patients.

**Dr. Patel reports no conflicts of interest.*

References




1. Mini Dental Implants for Long-Term Fixed and Removable Prosthetics: A Retrospective Analysis of 2514 Implants Placed Over a Five Year Period. Todd E Shatkin, DDS. Compendium February 2007;28(2):36-41.
 2. Clinical Evaluation of Small-Diameter Implants in Single-Tooth and Multiple-Implant Restorations: A 7-year Retrospective Study, Paolo Vigolo, International Journal of Oral & Maxillofacial Implants.
 3. Mini Implants: Good or Bad for Long Term Service?. Gordon Christensen, Journal Compilation 2008 Wiley Periodicals. Volume 20, Number 5, Moy PK, Medina D, Shetty V, Aghaloo TL. Dental implant failures rates and associated risk factors. Int J Oral Maxillofac Implants 2005;20(4):569-77.
 4. Flanagan D. A method for estimating preoperative bone volume for implant surgery. J Oral Implantol. 2000;26:262-266.
 5. Journal of Oral and Maxillofacial Surgery in 1997 (The influence of preoperative antibiotics on success of endosseous implants up to and including stage II surgery: a study of 2,641 implants. Dent C, Olson J, Farish S, Bellome J, Casino A, Morris H, Ochi S Journal of Oral and Maxillofacial Surgery December 1997 (Vol. 55, Issue 12 (Supplement), Pages 19-24).
 6. Leshem D, Maxor Z. A simple technique for fabrication of immediate interim removable prosthesis supported by transitional implants. Implant Dent 2003;12:227-231.

Author Bios

Dr. Paresh Patel is a graduate of UNC-CH School of Dentistry and the MCG/AAID MaxiCourse. He is the co-founder of the American Academy of Small Diameter Implants and is a clinical instructor at the Reconstructive Dentistry Institute. Dr. Patel has placed more than 2,500 mini-implants and has worked as a lecturer and clinical consultant on mini-implants for various companies. He can be reached at pareshpatelds2@gmail.com or on the Web at www.dentalminiimplant.com.



Dr. Andrea Mascolo is in private practice in Allessandria, Italy.

 Share 0  Tweet  Share  Save 0  Share

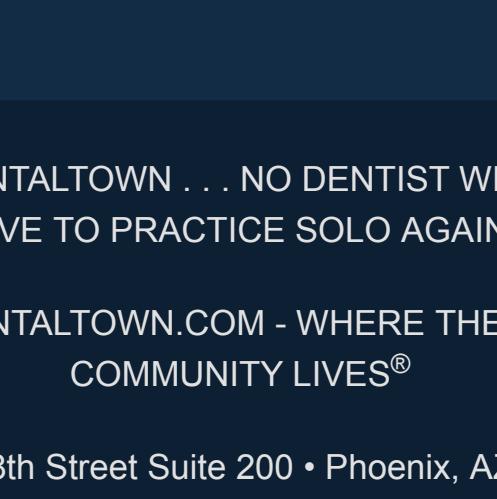
[add comment](#)

[view article pdf](#)

[more by this author \(6\)](#)

DentalTown Magazine


December 2018



Read Current Issue

Subscribe / Renew

Sponsors



THERE IS ONLY

The perfect radio show for Dentists looking for ANSWERS!

Townie® Poll

As a practice owner, do you or would you offer any forms of bonuses or incentives to employees?

Yes
 No

Company Info

contact us

advertise with us

howard farran dds, mba

privacy policy

terms of use

Communities

DentalTown

Hygienetown

Orthotown

Site Help

Sally Gross, Member Services

Phone: +1-480-445-9710

Email: sally@farranmedia.com

DentalTown Magazine

Macy Gross, Circulation

Phone: +1-480-445-9716

Email: macy@farranmedia.com

Follow DentalTown

Follow Howard

Mobile App

WITH DENTALTOWN . . . NO DENTIST WILL EVER HAVE TO PRACTICE SOLO AGAIN®

WWW.DENTALTOWN.COM - WHERE THE DENTAL COMMUNITY LIVES®

9633 S. 48th Street Suite 200 • Phoenix, AZ 85044 · Phone: +1-480-598-0001 · Fax: +1-480-598-3450

©1999-2019 DentalTown, L.L.C., a division of Farran Media, L.L.C. · All Rights Reserved