Research & Reviews

Research & Reviews: Journal of Dental Sciences

Search here..

MENU

e-ISSN: 2320-7949 and p-ISSN: 2322-0090

Reach Us +44-1625-708989

Small Diameter Implants (SDIs) in Fixed Restorations:Clinical Cases Considerations During 4 Years Follow-Up

Andrea Mascolo*

D.D.S, Master in Oral Surgery and Odontostomatological Urgency, Expert in Minimally Invasive Procedures, Italy

***Corresponding Author:**

Andrea Mascolo

Studio Mascolo

Leave a message

for
Dental Research and Dental Training
Viale A. Saffi 53 15067, Novi Ligure (AL) Italy
E-mail: andrea@studiomascolo.eu

Received: 21/09/2015 **Accepted:** 31/12/2015 **Published:** 10/01/2016

Visit for more related articles at Research & Reviews: Journal of Dental Sciences

View PDF | Download PDF

Abstract

In recent years, the interest and use of small diameter implants have increased considerably. The probable reasons are the clinical credibility in long term use and its minimally invasive placement protocol. Victor Sendax, a conceptualist and developer of small diameter implants, had identified three patients groups in the 1980's on which the mini implants offered invaluable performances: for medically, financially, and anatomically compromised patients. This paper outlines the clinical experience conducted among 28 patients during a follow-up period of four years. This group is heterogeneous in age, concurrent in systemic conditions and represents the type of a private practice patient whose treatments selected have followed the proposed guidelines for the rational use of small diameter implants.

Keywords

Small Diameter Implants (SDIs), Fixed Prosthesis, Crown, Minimally Invasive, Flapless Surgery

Introduction

Minimally invasive dentistry is a reality that in the last several years has involved all branches of dentistry. In implantology these minimally invasive techniques have revolutionized the standard treatments and are showing a high possibility of increased practice. Some examples applied in implantology include digital radiology, CT reconstructions, and their evolution with maximum reduction of radiation dose – CBCT Cone Beam to cite an example - and the software for three-dimensional reconstructions (advocated by Ganz already in 1995). The digital dentistry has and is continuing to contribute significantly to the growth and spread of minimally invasive dental treatments. These minimally invasive technologies have also stimulated the development of minimally invasive surgical techniques. Ten years ago, we were not talking about flapless or a sinus lift with crestal approach, whereas today minimally invasive procedures have achieved highly successful performance and predictability and they are used in a dental practice on daily basis [1]. The numerous advantages of the flapless surgery in implantology are well highlighted in the literature and are not just about minimizing surgical trauma but also achieving a fast healing process and good tissue response in the early stages of Osseointegration [2-4]. Strict guidelines are present in the literature about the directions of the flapless technique, and they have been proven to be highly functional in surgeries along with the use of software with the application of surgical guides [5,6]. The flapless procedure was applied with successful results on reduced diameter implants and was not only established to be safe but also decreases gingival healing period when combined with immediate loading [7].

Small diameter implants (SDIs), which were introduced to stabilize temporary dentures, were soon found to have several other clinical applications due to their high versatility [8,9]. For example, they have been used with a success in cases of limited interdental spaces [10,11]. Significant findings have been reported in the literature about the long-term survival of small diameter implants [12,13]. Guidelines are available in the literature about the surgical techniques and rehabilitation, and several evidences suggest fixed restorations with excellent long-term survival data [14,15]. Mini-invasive techniques offer both intraoperative and postoperative advantages, and they facilitate the healing of the tissues [16].

Some of the notable advantages are as follows:

1. Quicker healing postoperatively

2. Decreased potential of future bone loss around SDIs for the one-body design

3. Simpler placement protocols

4. Decreased waiting period until final prosthesis delivery compared to conventional implant treatment.

5. Anatomical limitations are lowered due to smaller

diameters of the implants.

6. A less invasive implant treatment option for medically compromised patients.

Some commonly discussed concerns among dentists about the use of small diameter implants (SDIs) for fixed restorations are as follows [17,18]:

1. A decreased surface area, therefore a potentially decreased metal fatigue resistance over the long term.

2. Lack of an emergence profile which could make gingival cleaning around the structure more difficult.

3. Since the crowns/bridges will essentially be a pontic design, the esthetic outcome on occasion might be compromised in the anterior areas.

Materials and Methods

The clinical protocol was applied on a heterogeneous in age, concurrent in systemic conditions and represents the type of private practice patient; the patients were treated from 2010 and 2013.

28 patients were selected: 15 females and 13 males ranging from 23 years to 66 years of age with a median value of 46 years (**Table 1**).

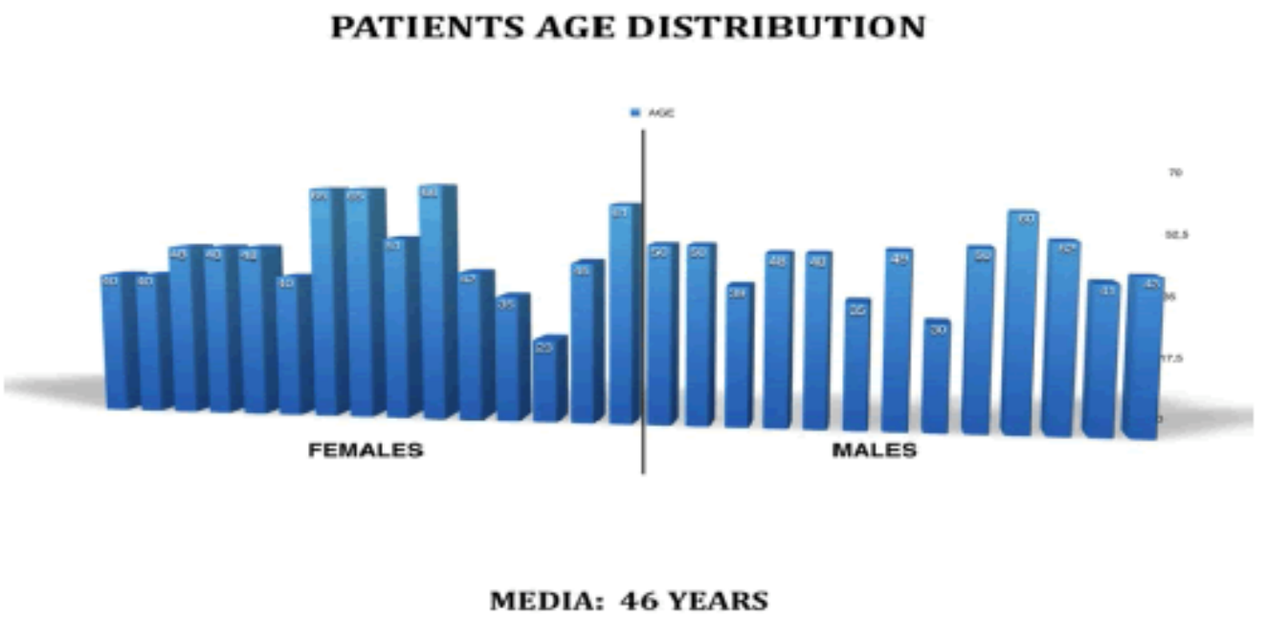

Table 1. Patients Age Distribution.

Table 1: Patients Age Distribution.

11 patients were smokers while 11 patients presented rather common systemic conditions such as hypertension and allergies to certain medications (**Table 2**).

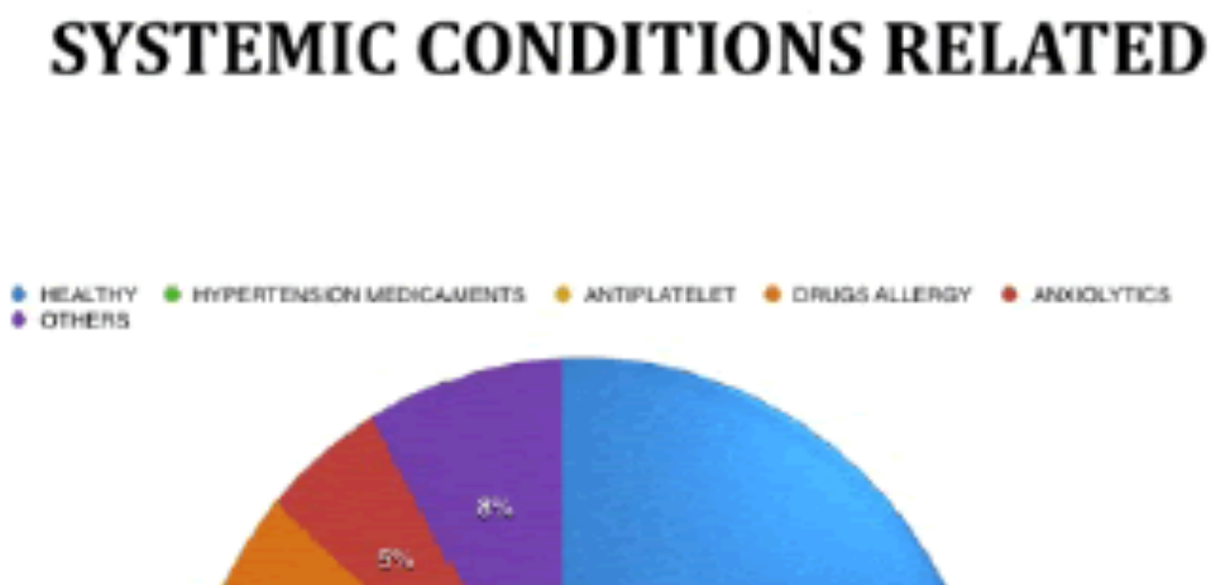

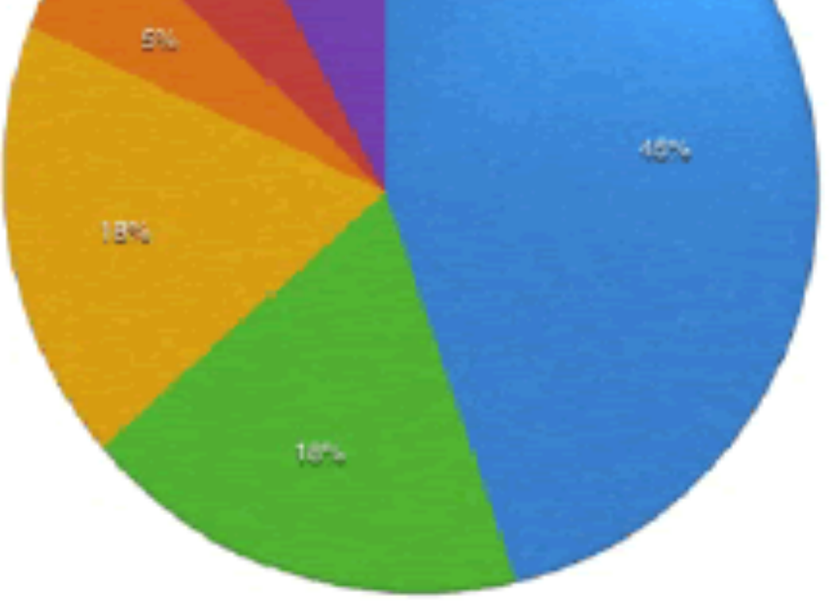

Table 2. Systemic Condition related.

Table 2: Systemic Condition related.

48 SDI's diameter 2.5 mm were placed with lengths from 11.5 mm to 18 mm with 13 mm being the most common length (**Table 3**).



Table 3. Small Diameter Implant Lengths

Table 3: Small Diameter Implant Lengths.

The author has preferred diameter 2.5 mm and wider threads, for the maxillary restoration and the areas with a softer bone as the cases selected in jaw; the clinical experience and the evidences suggest the small diameter implants diameter 2 mm with finer threads in a denser bone as known in physiology in anterior mandible, to reduce the excessive insertion torque and potential pressure necrosis [19,20].

All of placements were carried out with a flapless approach.

The SDIs were loaded as follows: 5 SDIs were immediate loaded while 43 SDIs were loaded after 3 months considering the initial critical stability period around to 3 weeks and the osseointegration period of 3 months as suggested in the initial guidelines [14].

When the implants were loaded, the crowns and bridges were loaded with light contacts as with the conventional implants.

Patient satisfaction was investigated after the surgical procedure through VAS (visual analogue scale) for post-operative pain after one hour and also again eight hours after surgery. During the revaluation, the VAS was used to assess the satisfaction of the patient relative to the treatment performed [21].

The clinical evaluation was achieved from 18 to 50 months with 29 months being the mean evaluation period (**Table 4**). The period of 18 months represents the minimum follow-up suggested by the literature to evaluate the long-term restoration [22,23]. It is stated that in 28 patients selected: 5 patients (18%) have a follow-up from 18 to 20 months while 7 patients (25%) have a followup 40 months or over (4 patients indeed over than 4 years).

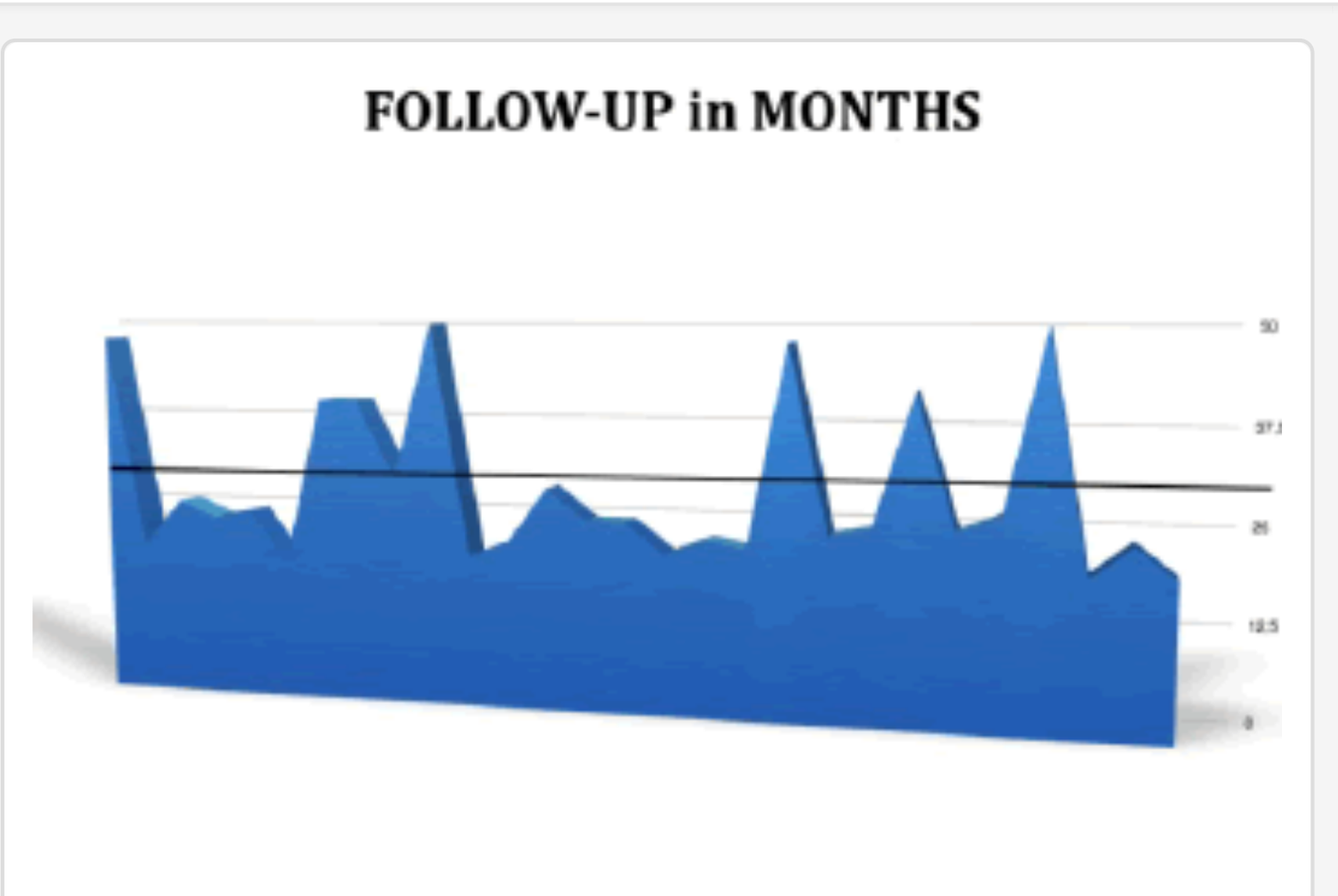

MEDIA: 29 MONTHS

Table 4. Follow-Up in Months.

SURGICAL PROTOCOL

Table 4: Follow-Up in Months.

Surgical Protocol

Just prior to the surgery, a rinse with 0.20% chlorhexidine was performed and then the tongue and the gums was cleansed around the surgical site with gauze soaked in 0.20% chlorhexidine; Mepivacaine with epinephrine 1:100,000 was the local anesthetic used.

The surgical procedure was flapless with a "punch" technique in 95% of all of the cases and in only two cases the procedure was flapless with a "mini incision" technique.

CASE 1: 40 years old Caucasian female, non-smoker, no meds at the time of the treatment.

(**Figures 1-10**).

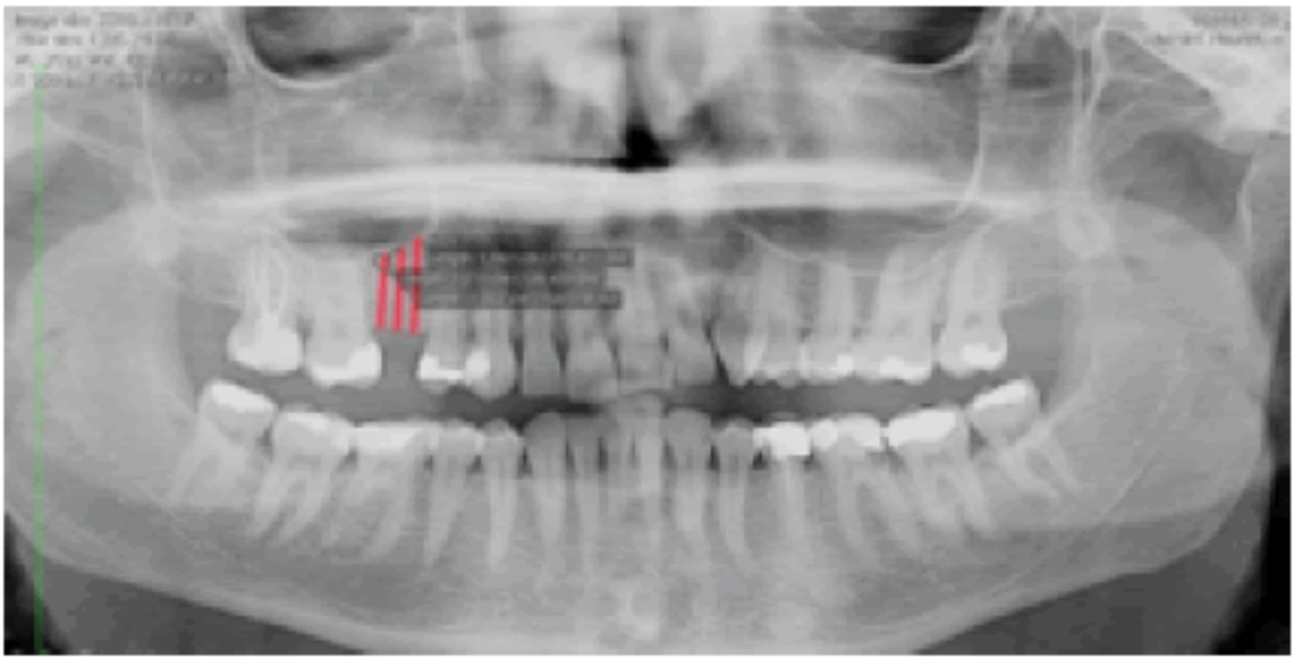

Figure 1. Initial OPG.

Figure 1: Initial OPG.

Figure 2. Initial clinical view.

Figure 2: Initial clinical view.

Figure 3. Initial clinical view: reduced residual ridge.

Figure 3: Initial clinical view: reduced residual ridge.

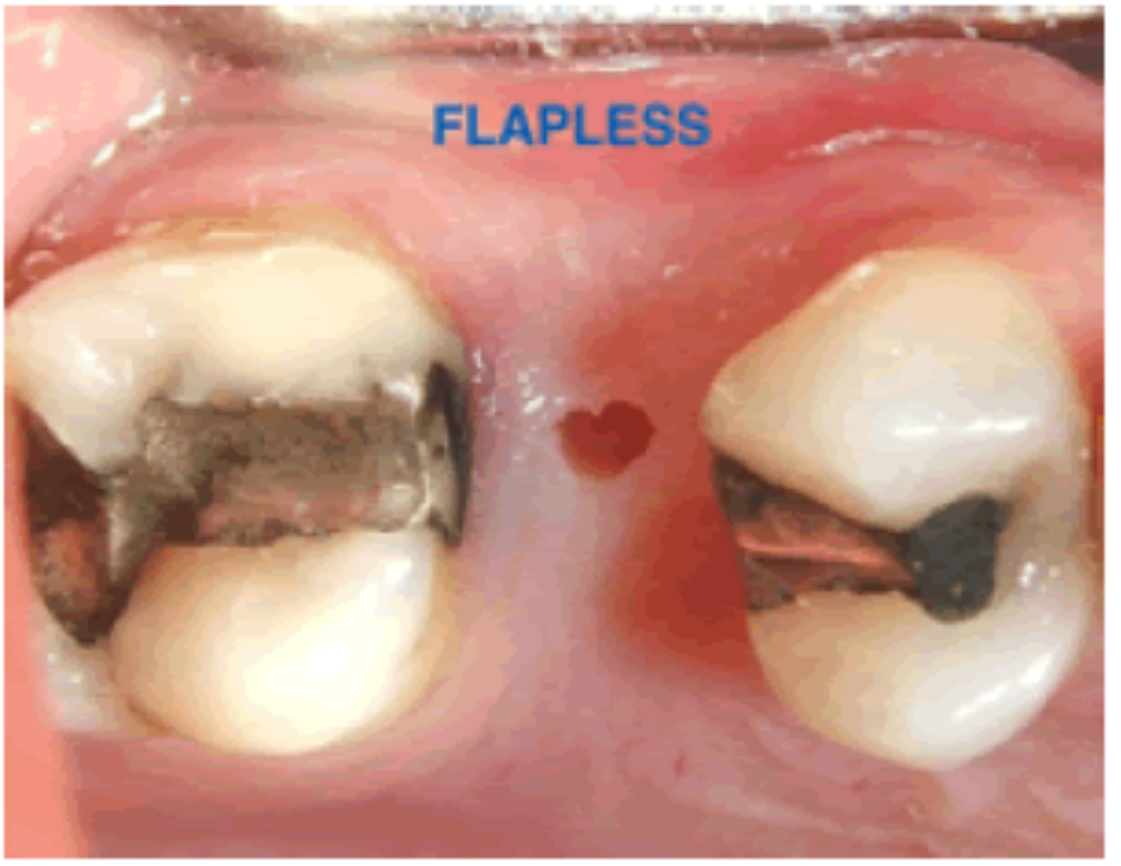

Figure 4. Intra surgery: flapless procedure.

Figure 4: Initial clinical view: reduced residual ridge.

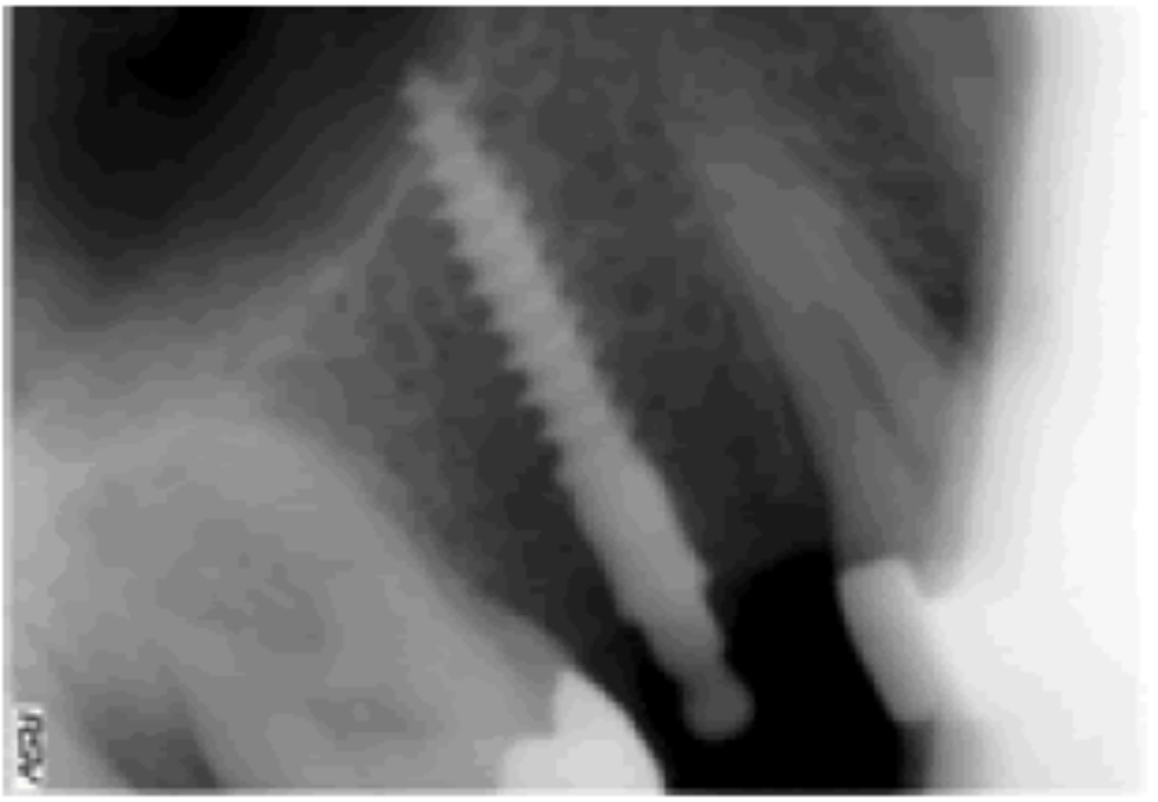

Figure 5. X-Ray immediate after surgery.

Figure 5: X-Ray immediate after surgery.



Figure 6. X-Ray immediate after surgery with contrast.

Figure 6: X-Ray immediate after surgery with contrast.

Figure 7. Clinical revaluation: 18 months after prosthetic restoration.

Figure 7: X-Ray immediate after surgery with contrast.

Figure 8. Clinical revaluation 18 months: complete gum remodeling around the restoration.

Figure 8: Clinical revaluation 18 months: complete gum remodeling around the restoration.

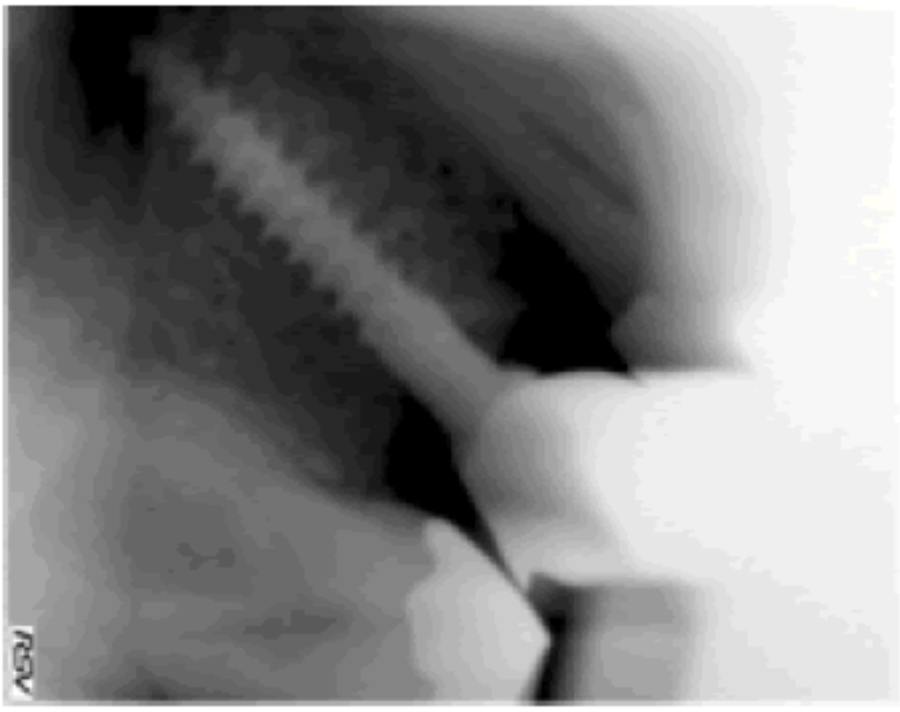

Figure 9. X-Ray 18 months after prosthetic restoration.

Figure 9: X-Ray 18 months after prosthetic restoration.



Figure 10. X-Ray 18 months after prosthetic restoration with contrast.

Figure 10: X-Ray 18 months after prosthetic restoration with contrast..

In many cases, a surgical guide was provided to simplify the parallelism of the implants. The surgical protocol for the insertion of the small diameter implants MDL™ (Intra-Lock International®;) requires a partial osteotomy with a single 1.2 mm drill for a third of the length of the implant. A full osteotomy is not necessary due to the self-tapping/self-drilling nature of SDI's.

The loading of the implants were performed according to the guideline prescriptions. Immediate loading was applied only to those patients with high bone density and a high torque intersection (more than 35 Ncm) [24-26].

The average time of evaluation for the process of osseointegration was three months [13,14,27]. The average time for the insertion of the small diameter implant was calculated at around seven minutes with a considerable reduction of the surgical time even where the guidelines provided for a greater number of fixtures - two SDI's for a molar, for example [15,27].

The post-surgical treatment included 600 mg ibuprofen after the surgery and the application of ice was recommended for 3 hours after the surgery. The recommendation was then 400 mg ibuprofen twice every eight hours after the first dose and then afterwards as the patient needed. **Antibiotic** therapy was prescribed (amoxicillin and clavulanic acid three days after treatment every 12 hours) only in patients with an infectious risk.

The post-surgical therapy included the use of 0.20% chlorhexidine twice daily for 10 days following the surgery.

Post-surgical pain was evaluated by VAS (visual analogue scale) one hour after surgery and again eight hours after surgery.

Results

35 teeth in total were restored: 25 teeth restored in the maxillary arch that is a suspected area to have more implant failure due to generally lower bone density with greater prevalence for premolars and molars; 10 teeth restored in the jaw (**Tables 5** and **6**).

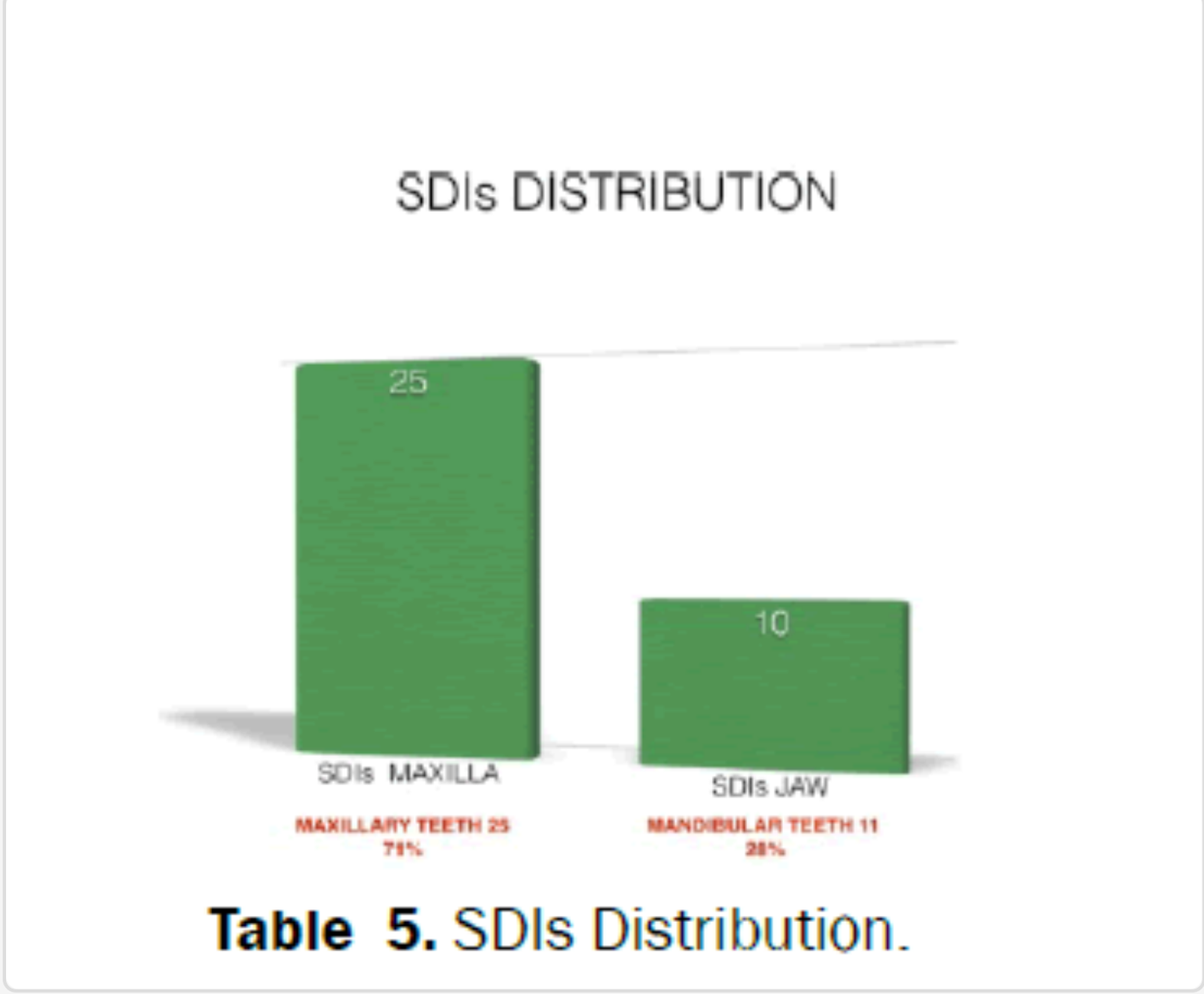

Table 5: SDIs Distribution.

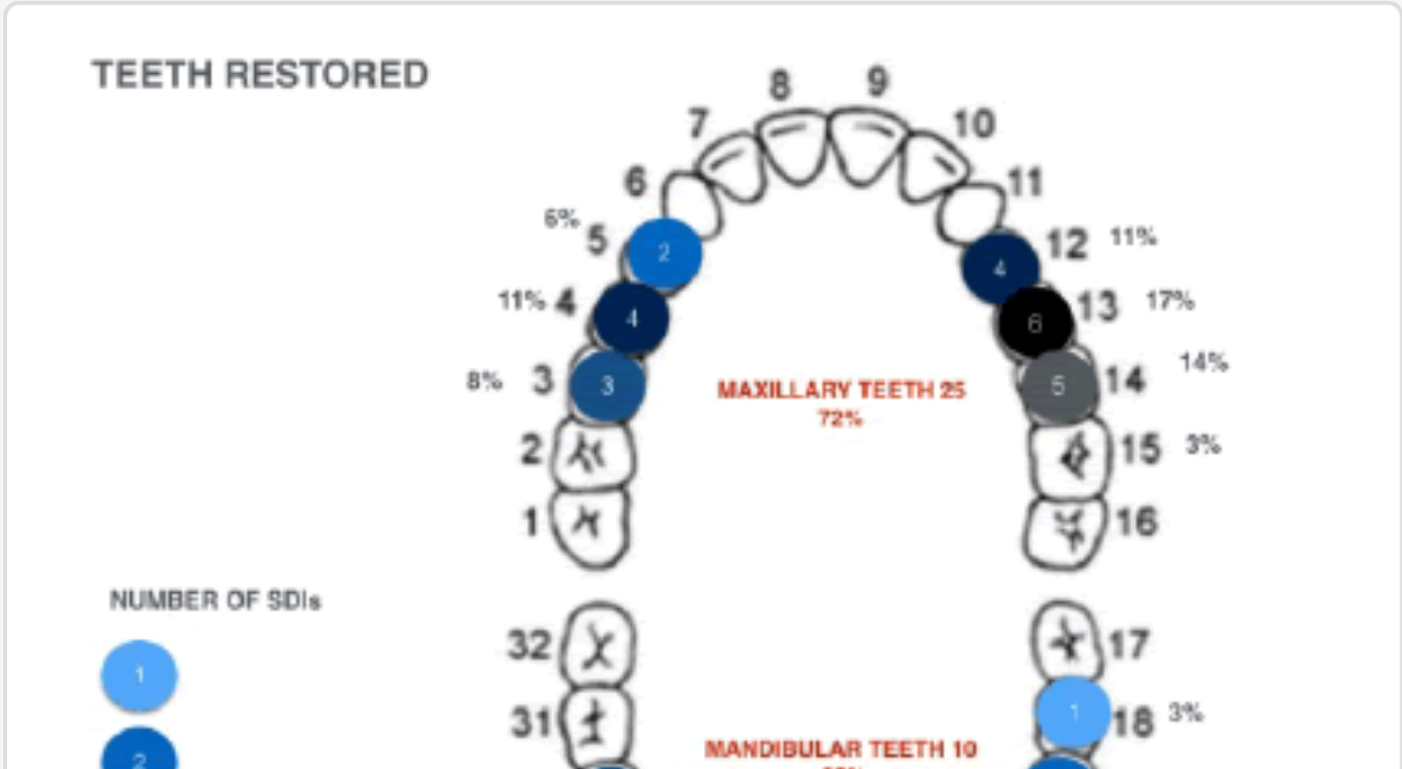

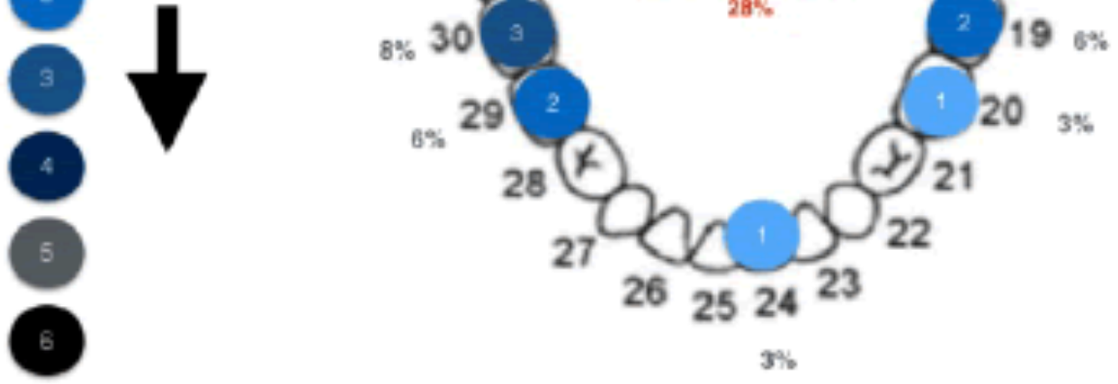

Table 6. Teeth Restored.

Table 6: Teeth Restored.

CASE 2: 66 years old Caucasian female, non-smoker, antiplatelet therapy during the surgical procedure not suspended.

The results show no loss of bone around the small diameter implants during the period of the follow-up. The revaluation was conducted radiologically (**Figures 11-17**).

CASE 3: 43 years old Caucasian male, smoker > 20/die, no meds at the time of the treatment.

Figure 11. Initial clinical view.

Figure 11: Initial clinical view.

Figure 12. Intra surgery: flapless procedure no bleeding.

Figure 12: Intra surgery: flapless procedure no bleeding.

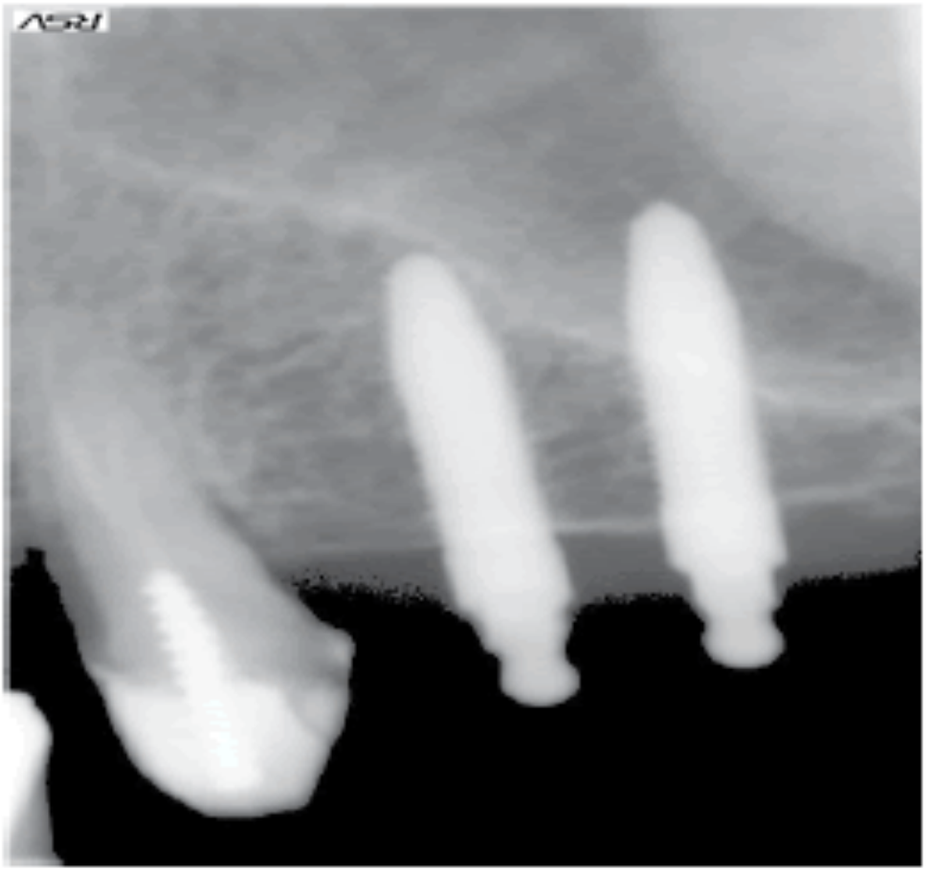

Figure 13. X-ray immediate after surgery.

Figure 13: Intra surgery: flapless procedure no bleeding.



Figure 14. PFM restoration.

Figure 14: PFM restoration.

Figure 15. PFM restoration cemented.

Figure 15: PFM restoration cemented.

Figure 16. Clinical revaluation 50 months.

Figure 16: Clinical revaluation 50 months.



Figure 17. X-ray revaluation 50 months.

Figure 17: X-ray revaluation 50 months.
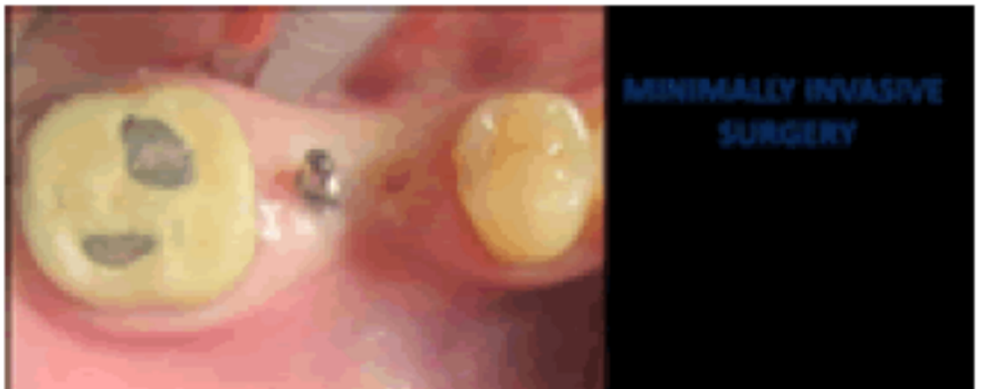
The perimplant soft tissues were trophic and well occlusive; the implant diameter and the one -body design with cemented abutment able to seal the perimplant area eliminating micro-leakages may play a key role in pink tissue outcomes (**Figures 18-23**).